J. Bangladesh Agril. Univ. 3(1): 87–94, 2005 ISSN 1810-3030

Avian liver fluke infection in indigenous ducks in Bangladesh: prevalence and pathology

Anisuzzaman[1], M.A. Alim[1], M.K. Islam[1], P.M. Das[2], T. Farjana[1] and M.M.H. Mondal[1]
[1]Department of Parasitology, Bangladesh Agricultural University, Mymensingh-2202
[2]Department of Pathology, Bangladesh Agricultural University, Mymensingh-2202

Abstract

The prevalence and pathological effects of the trematodes in liver and gallbladder of the indigenous ducks in Bangladesh were investigated during the period from July 2003 to June 2004. Out of 300 ducks examined, 208 (69.33%) ducks were infected with one or more species of avian liver flukes. The liver fluke species, recovered from the liver and gallbladder were: *Metorchis orientalis* (55.33%), *Amphimerus anatis* (54.33%), *Amphimerus lancea* (12.00%) and *Amphimerus caudalitestis* (1.00%). The highest prevalence was recorded in monsoon (91.30%) followed by winter (76.51%) and summer (49.52%). Similarly, the parasitic load was relatively higher in monsoon (23.10±3.10) followed by winter (18.76±2.98) and summer (08.99±2.95). The prevalence of the trematodes was significantly ($P<0.01$) higher in adult ducks (82.61%) than in the young ducks (25.71%). The mean parasitic density was also higher in adult ducks (25.24±3.99) of > 6 months age than in the young ducks (06.91±1.39) of < 6 months age. Almost similar rate of infection was recorded in male (70.71%) and female (68.13%) ducks with an average parasitic burden of 26.41±3.54 and 24.92±2.96 respectively. In most cases, the parasitized liver was slightly atrophied characterized by the smaller size with shrinkage or wrinkling of the liver capsule. The edges or borders of the livers were sharp along with tiny white necrotic foci in some cases. On cut surface, the parasites were found in the bile ducts but no calcification was detected. Grossly, gallbladder was apparently normal containing adult parasites in it. Histopathologically, cross-section of parasites with their eggs and cellular debris were found within the bile ducts. Desquamation of the bile duct epithelium was observed but in some cases, the bile duct epithelium was hyperplastic in nature. Microabscesses with infiltration of lymphocytes, macrophages and polymorphonuclear cells predominantly neutrophils were revealed in the hepatic lobules. Proliferation of the fibroblasts occurred around the bile ducts. But in advanced cases, extensive fibrosis observed which extended from the portal triads to the adjacent hepatic lobules resulting disorganization of the normal hepatic architecture leading to cirrhosis. In severe cases, the normal structures of the bile ducts were almost obliterated by the extensive proliferation of the fibroblasts converting it into a fibrous tube. This study suggests that the avian liver flukes of the indigenous ducks of all ages and sexes may be a major problem.

Keywords: Avian liver fluke, Indigenous ducks, Prevalence, Pathology

Introduction

In Bangladesh, 98% ducks are reared in semi-scavenging system (BBS 2001). Excepting a very small quantity of feed supplement by the farmers at evening, in the day time the ducks forage for their food in water pools, lakes, rice fields and swamps to get weeds, snails, small fishes, earth worms, insects and algae. This natural habit of collecting feed exposes them to high risk of parasitic infection especially by the snail borne trematodes. Among the trematodes, avian liver flukes especially *Metorchis orientalis* and different species of *Amphimerus* found in bile ducts and gall bladder of ducks are very common (Soulsby, 1982; Lapage, 1962). Sometimes *M. orientalis* may act as the main cause of liver disease in ducks (Zhang *et al.*, 1994). Moreover, *M. orientalis* is a parasite of zoonotic importance (Lin *et al.*, 2001). In Bangladesh, prevalence of parasitic infections in domestic ducks has been reported by earlier scientists (Ahmed, 1969, Qadir 1979, Islam *et al.*, 1988). This paper will describe

the prevalence of avian liver flukes infections in indigenous domestic ducks in relation to the age and sex of the host, seasons of the year and the pathological lesions produced by the parasites in hosts.

Materials and Methods

The study was conducted in the Parasitology Laboratory, Department of Parasitology, Bangladesh Agricultural University, Mymensingh, from July 2003 to June 2004. A total of 300 indigenous ducks reared under semi-scavenging system were purchased from local markets of different areas of Mymensingh district and slaughtered for post-mortem examination following the standard procedure as described by Fowler (1990). Liver and gallbladder of the slaughtered ducks were examined carefully to detect the pathological lesions if any. The gallbladder was removed from the liver and opened in a petridish containing sufficient amount of normal saline. The liver was cut into small pieces of about 1 cu. cm size and kept into normal saline in a separate petridish for about one hour. Then the pieces were pressed gently so that the remaining parasites may come out. The tissues were removed and the washings were made clear by several sedimentations. The washings were examined and parasites were collected by the help of a dropper. The parasites were preserved in 10% formalin. The detail morphological characteristics were studied by preparing permanent slides according to the procedure as described by Cable (1957). The gross pathological lesions were recorded and the affected organs were collected and preserved in 10% buffered neutral formalin. For histopathological study, slides were prepared following the methods as described by Luna (1968). Parasites were identified according to the keys given by Yamaguti (1958) and Soulsby (1982). For the convenience of the study of seasonal dynamics, the year was divided into three seasons such as monsoon (July to October), winter season (November to February) and summer (March to June). To study the influence of age, the ducks were divided into two categories such as adult ducks (>6 months of age) and young ducks (< 6 months of age). In ducklings, sexes were identified by the digital palpation of penis according to the procedure as described by Parkhurst and Mounteney (1988). The data were analyzed by SPSS package program by using t-test.

Results and Discussion

Out of 300 ducks examined, 208 (69.33%) were infected with the avian liver flukes. The recovered liver flukes were *M. orientalis, A. anatis, A. lancea* and *A. caudalitestis*. The infection rate of *M. orientalis* and *A, anatis* was 55.33% and 54.33% respectively while 12% ducks had *A. lancea* and 1.00% ducks had *A. caudalitestis* infection (Fig.-1). The age barrier of the ducks significantly influenced the prevalence of the parasitic infection and the load of parasites in hosts. Significantly ($P<0.01$) higher rate of infection was recorded in the adult ducks (82.61%) than that in young ducks (25.71%). There was variation in the prevalence of different species of liver flukes among the adult and young ducks. *A. caudalitestis* was recorded only in adult ducks (1.30%). Almost similar rate of prevalence of *A. anatis* (66.09%) and *M. orientalis* (65.22%) was recorded in adult ducks while *A. lancea* affected 13.91% adult ducks. In young ducks, the infection rate of *M. orientalis, A. anatis and A lancea* was 22.86%, 15,71% and 5.71% respectively (Table 2). The mean parasitic burden was significantly ($P<0.01$) higher in adult ducks (25.54±3.99) than that of young ducks (06.91±1.39). Unlike the age, the sex variation had very little influences on the prevalence of infection and load of parasites in ducks. Almost similar rate of infection was recorded in male (70.71%) and female ducks (68.13%). Among the parasites recorded, *M. orientalis* was the most prevalent in male

(65.00%) while *A. anatis* infection was relatively higher in female ducks (52.50%). *A. caudalitestis* was recorded only in male ducks (2.14%). Detail has been given in the table 2. An average load of liver fluke was little bit higher in male (26.41±3.54) than the female (24.92±2.96) ducks. The prevalence of these parasitic infections varied significantly ($P<0.05$) in different seasons of the year. The highest number of ducks was infected in monsoon (91.30%) followed by winter (76.51%) and the lowest in summer (49.52%). Again, to consider the prevalence of individual parasitic infection in different seasons, the highest prevalence of all parasites was encountered in monsoon followed by winter and the lowest in summer. *A. caudalitestis* was recorded only in the monsoon (Table 1). The seasonal fluctuation of the year also affected the parasitic load. Irrespective to the parasite species, the average parasitic load was relatively higher in monsoon (23.10±3.10) followed by winter (18.76±2.98) and summer (08.99±2.95). Statistically insignificant differences were observed in the burden of individual parasites in different seasons of the year (Table 1).

Table 1. Seasonal prevalence of avian liver fluke infections in indigenous ducks

Seasons	Name of parasites	No. of ducks infected (%)	Range	Mean ±SD
Monsoon (July-October) N=46	*M. orientalis*	34 (73.91)	2-50	10.29±02.12
	A. anatis	31(67.39)	2-30	4.80±03.15
	A. lancea	10(21.74)	1-04	2.50±01.58
	A.caudalitestis	03(06.52)	1-04	2.67±01.97
Winter (November-February) N=149	*M. orientalis*	81(54.36)	3-30	7.24±03.91
	A. anatis	90(60.40)	2-40	4.01±01.57
	A. lancea	20(13.42)	2-06	2.79±01.43
Summer (March-June) N=105	*M. orientalis*	50(47.62)	2-41	8.81±03.97
	A. anatis	42(40.00)	4-36	5.10±02.73
	A. lancea	06(05.71)	2-08	2.17±01.21

Table 2. Age and sex related prevalence of avian liver fluke infections in indigenous ducks

Factors	Categories	Name of parasites	No. of infected ducks (%)	Range	Mean±SD
Age	Adult N=230	*M.orientalis*	150(65.22)	6-50	12.29±3.53
		A. anatis	152(66.09)	4-40	7.91±1.99
		A. lancea	32(13.91)	3-8	2.11±0.96
		A. caudalitestis	03(01.30)	1-4	2.67±1.11
	Young N=70	*M.orientalis*	16(22.86)	2-11	4.95±2.19
		A. anatis	11(15.71)	2-4	3.71±1.94
		A. lancea	04(05.71)	1-2	2.26±1.29
Sex	Male N=140	*M.orientalis*	91(65.00)	2-50	10.19±3.01
		A. anatis	79(56.43)	2-40	6.15±1.37
		A. lancea	16(11.43)	1-5	2.17±0.76
		A. caudalitestis	03(02.14)	1-4	2.67±1.08
	Female N=160	*M.orientalis*	75(46.88)	2-19	5.58±2.18
		A. anatis	84(52.50)	3-33	5.21±2.32
		A. lancea	20(12.50)	1-8	3.11±1.89

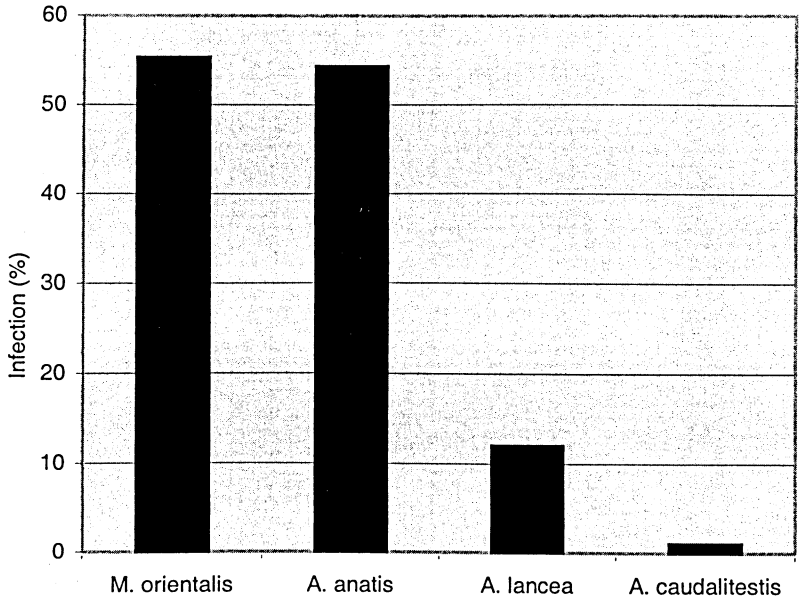

Fig-1. Prevalence of avian liver flukes in ducks

Fig. 2. Chronic severe active hepatitis characterized by the infiltration of reactive cells predominantly with neutrophils, and presences of cross sections of the parasites with their eggs (10X)

Pathology of avian liver fluke infection

In most of the cases, the infected livers were slightly atrophied characterized by smaller size of the liver along with shrinkage or wrinkling of the liver capsule. The edges of the livers were sharp. Small white spots were observed on the parietal surface of some affected livers. Parasites emerged from the cut surface. Neither calcification nor metallic or gritting sound was detected when the liver was cut. Although the adult parasites were recovered from the gallbladder but no pathological changes were detected in the gallbladders. Histopathologically, in some cases, the sections of livers were diagnosed as "chronic severe active hepatitis" characterized by the infiltration of lymphocytes, macrophages, and polymorphonuclear cells predominantly with neutrophils. Proliferation of fibroblasts occurred around the larger bile ducts. Cross sections of the parasites with their eggs and cellular debris were present in the lumen of the bile ducts (Fig.-2.). But in advanced stages, active cellular reaction subsided whereas the repairing processes were more pronounced. At this stage, extensive fibrosis observed which extended from the portal triads to the adjacent hepatic lobules resulting disorganization of the normal hepatic architecture leading to cirrhosis. Bile duct of the affected liver was dilated. In some cases, desquamation or hyperplasia of bile duct epithelium was detected in association with fibroblasts proliferation. But in advanced stages, normal structures of the bile ducts were almost replaced by the extensive proliferation of the fibroblasts turning the bile ducts simply into a fibrous tube. However, deposition of inorganic salts such as calcification of bile ducts was not observed in this study. No migratory tracts or hemorrhages were observed either grossly or histopathologically.

The present study revealed an overall high rate of prevalence (69.33%) of avian liver fluke infections (*M. orientalis*, *A. anatis, A. lancea* and *A. caudilitestis*) in indigenous ducks in Bangladesh. The prevalence of *M. orientalis* (55.33%), *A. Anatis* (54.33%), *A. lancea* (12%) and *A. caudalitestis* (1.00%) is much higher than it was reported by the earlier scientists (Islam *et al.*, 1988) who reported *Amphimerus* sp. infection in 23% indigenous ducks in Bangladesh. This difference might be due to the gradual changes in the climatic conditions, patterns of cultivation and irrigations of lands etc. over the period of about last two decades. Wang (1997) recorded 9.30% *M. orientalis* infection in domestic ducks in China while 18.33% prevalence of *M. orientalis* in ducks in Huaihe river basin in China was reported by Li and Wang (2003). On the other hand, Lin *et al.* (2001) found that the infection rate of *M. orientalis* was 66.70% in ducks in Pin Yuan County of Guangdong province in China. These discrepancies between reports of Bangladesh and other parts of the world might be due to the differences in the geo-climatic conditions of the areas, breed of the ducks, distribution and the availability of the intermediate and reservoir hosts and method of study. The causes of difference in the rate of prevalence of different parasites are difficult to explain, but the variation in the host susceptibility, fecundity of the parasites; survival capacity of the infective stages of the parasites in the environment may contribute to the different infection rate in ducks. Moreover, the stray dogs and cats of Bangladesh may play an important role in the dissemination of *M. orientalis* infection because they act as reservoir host of *M. orientalis* (Cheng *et al.* 2000). A significantly ($P<0.01$) higher rate of infection with *A. anatis* in adult

ducks (66.09%) than in the young ducks (15.71%) conforms to the earlier reports of Islam *et al.* (1988) who showed that adult ducks were more frequently infected than the young ducks of 02 to 20 weeks old. The higher infection rate in adult ducks might be related with the differences of food habits of ducks in different age groups. In rural areas of Bangladesh, ducks are reared mostly in semi-scavenging system where young ducks are usually supplied with boiled rice, rice bran and other household wastages, earthworms, and small crustaceans. But the adult ducks are usually scavengers and commonly feed on various aquatic animals including snails, fresh water fishes, small frogs from the water bodies. According to Yang and Lai (1998) metacercarial cysts of *A. anatis* were not infective until they had developed within the second intermediate hosts like various fresh water fishes and in some amphibians like frogs. Fresh water fishes also act as second intermediate host in the life cycle of *M. orientalis* (Soulsby, 1982). So the chances of getting infection with these parasites in adult ducks are very high. Moreover, the immunological phenomenon may play a role where a reverse age resistance phenomenon may be present which makes the young ducks more resistant to infection. The almost similar rate of infection in male (70.71%) and female ducks (68.13%) is in agreement with the findings of Islam *et al.* (1988) who recorded 21.81% and 24.44% infection in male and female ducks respectively. Among the flukes, the prevalence of *M. orientalis* infection varied significantly ($P<0.05$) in the two sex groups. It is very difficult to explain why the prevalence of *M. orientalis* is higher in male ducks (65.00%) than the female ducks (46.88%) and *A. caudalitestis* was only present in male ducks. But in Hampshire chickens, it has been observed that male sex hormone made the individuals more susceptible to some parasitic infection (Ackert and Dewhrist 1950). Todd and Hollingworth (1951) conducted an experiment with *Ascaridia galli* in chickens and observed fewer warm burden in female compared to male. It may be likely that sex hormone may influence the susceptibility of male ducks to *A. caudalitestis* infection. The highest prevalence of the avian liver flukes observed in the monsoon (91.30%) followed by winter (76.51%) and summer (49.52%) cannot be compared due to paucity of the relevant literatures. However, the temperature, rainfall and humidity of the monsoon might be favourable for the development and survival of the different developmental stages of these parasites. Besides, the population of various aquatic snails, fresh water fishes and amphibians (frogs) are more in this season, which act as the intermediate hosts of *Amphimerous* spp. and *Metorchis orientalis* (Yang and Lai, 1998; Joo, 1988; Soulsby, 1982). On the other hand, snails, frogs etc. undergo hibernation in the winter and aestivation in the summer. Moreover, in Bangladesh, vast areas of lands go under water or become flooded in the monsoon, which helps in the spread of infection to the large duck population through out the country. Possibly, due to the above-mentioned causes the prevalence of these parasites is higher in monsoon in indigenous domestic ducks in Bangladesh.

Gross pathological lesions of the affected liver characterized by its smaller size, shrinkage or wrinkling of the liver capsule associated with small white spots on the parietal surface can not be compared due to lack of information on the pathology of avian liver flukes since very little research effort has been made to study the pathology of these trematodes. This study did not record acute gross lesions as those have been described in case of fascioliasis in ruminants (Soulsby, 1965). This finding suggests that liver fluke infections of ducks may be chronic in

nature. Histopathologically, desquamation and hyperplasia of bile ducts epithelium occurred possibly from the traumatic injury induced by the chronic irritation of the adult parasites on the bile duct wall. Similar types of desquamation and hyperplasia of bile duct epithelium had been reported by Soulsby (1965) due to *Opisthorchis felineus* infection in dogs. Urquhart *et al.* (1999) reported that hyperplasia of bile duct epithelium was a common feature in case of fascioliasis in ruminants. The bile ducts occupied by the trematodes were distended and they usually exert pressure on the surrounding tissues resulting variable degrees of tissue destructions. These destroyed tissues were repaired by the proliferation of fibroblasts resulting biliary cirrhosis as it has been reported in case of dicrocoeliasis and fascioliasis (Soulsby, 1965) in ruminants. Cellular infiltration with lymphocytes, macrophages and polymorphonuclear cells, predominantly with neutrophils were observed but no eosinophilic infiltration was detected. Absence of eosinophilic infiltration is in contrast to the earlier findings for fasciolosis in buffaloes (Alim *et al,* 2000) and *Fascioloides magna* infection in sheep (Jones *et al.*; 1997). However, Jones *et al.* (1997) described the absence of eosinophilic infiltration in case of *Spirocerca lupi* infection in dogs.

Acknowledgement

The authors thankfully acknowledge the SLDP-2 (Small Holder Livestock Development Project) DANIDA, authority for the financial support to conduct the research works.

References

Ackert, J. E. and Dewhirst L. W. 1950. Resistance of fowls to parastism affected by female sex hormone. *Journal of Parasitology,* 36:16.

Ahmed, S. 1969. Survey on the type of helminths commonly found in country ducks. *Pakistan Journal of Veterinary Science*, 3: 110-114

Alim, M. A.; Mondal, M. M. H.; Islam, M. K. and Khan, M. A. H. N. A. 2000. A note on the pathology of *Fasciola gigantica* and *Gygantoctyle explanatum* in the livers and gall bladders of buffaloes. *Bangladesh Veterinary Journal.* 17(2) : 124-125.

BBS 2001.*Statistical Pocket Book of Bangladesh,* Bangladesh Bureau of Statistics, Ministry of Planning, Government of the People Republic of Bangladesh, Dhaka, Bangladesh.

Cable, R. M. 1957. *An Illustrated Laboratory Manual of Parasitology.* Burgess Publishing Co., 426, South Sixth Street, Minneapolis 15, Minnesota.

Cheng Y.Z.; Li Y. S.; Xu, Y. D.; Yang, W. C.; Wang, Q. and Shi, L.2000. Survey on mixed infections with fish borne trematodes in Pinyuan county and DNA analysis, *Chinese Journal of Zoonoses*, 16-3, 52-55.

Fowler, N. G. 1990. How to carry out a field Investigation In: *Poultry Diseases*, Jordan F, T. W. (Ed.) Bailliere Tindall, London, pp. 370-400.

Islam, M. R.; Shaikh, H. and Baki, M. A. 1988. Prevalence and pathogenecity of helminth parasites in domestic ducks of Bangladesh, *Veterinary Parasitology* 29:73-77

Jones, T.C.; Hunt, R. D. and King, N. W. 1997. *Veterinary Pathology*, 6th Edn. 351 West Camden Street Baltimore, Maryland, USA, p 661

Joo, C. Y. 1988. Changing patterns of infection with digenetic lerval trematodes from fresh in river Taewha, Kyongnam province, *Korean Journal of Parasitology*, 26:263-274.

Lapage, G. 1962. *Morning's Veterinary Helminthology and Entomology*, 5th edn. Bailliere Tindall and Cox Ltd. UK. pp. 264-266.

Li, C.P. and Wang, J.2003. Preliminary study on ecology of *Metorchis orientalis* in Huaine river basin in China, *Chinese Journal of Parasitic Disease control*, 16:2, 108-110.

Lin, J.; Chen Y.Z. and Li, Y.S. 2001. The discovery of natural infection of human with *Metorchis orientalis* and the investigation of its focus, *Chinese Journal of Zoonoses*, 17:4, 19-23.

Luna, L. G. 1968. *Manual of Histopathologic Staining Methods of the Armed Forces Institute of Pathology*. 3rd edn. McGrow-Hill Book Comp. London.

Parkhurst, C. R. and Mounteney, G. J. 1988. *Poultry Meat and Egg Production*, CBS Publishers and Distributors, New Delhi-110002, India pp227-285.

Qadir, A. N. M. A. 1979. Helminth parasites of domestic ducks (*Anas boschas domesticus*) in Mymensingh district, *Bangladesh Veterinary Journal*, 13: 43-45

Soulsby, E. J. L. 1982. *Helminth, Arthopod and Protozoa of Domesticated Animals*. 7th edn. Bailliere Tindall, London, UK.

Soulsby, E. J. L. 1965. *Textbook of Veterinary Clinical Parasitology*, Blackwell Scientific Publications, Oxford.

Todd, A. C. and Holligsworth, K. P. 1951. Host sex as a factor in development of *A. galli, Experimental Parasitology*, 2:102-108.

Urquhart, G. M., Armour, J., Duncun, J. L., Dunn, A. M. and Jennings, F. W. 1999. *Veterinary Parasitology*, 2nd edn. Blackwell Science Ltd.

Wang, S.K.1997. Study on spatial distribution patterns of *Metorchis* trematodes in their host population of domestic ducks, *Acta Parasitologica et Medica Entomologica Sinica*, 4:3,139-144.

Yamaguti, S. 1958. *Systema Helminthum*. Vol. III Interscience Publishers, Inc. New York,

Yang G. Y. and Lai, W.M 1998. Studies on the life cycle of *Amphimerus anatis, Acta Veterinaria et Zootechnica Sinica* 29:6,564-569.

Zhang C. J., Wang B.A. and Zhu K.X 1994. Studies on the pathogenecity and carcinogenecity of duck hepatitis B virus. Relationship between duck hepatits B virus in sera and pathological changes in the liver of ducks. *Journal of Jiangsu Agricultural College* 15: 2, 19-26