AgEcon SEARCH
RESEARCH IN AGRICULTURAL & APPLIED ECONOMICS

The World's Largest Open Access Agricultural & Applied Economics Digital Library

This document is discoverable and free to researchers across the globe due to the work of AgEcon Search.

Help ensure our sustainability.

Give to AgEcon Search

AgEcon Search
http://ageconsearch.umn.edu
aesearch@umn.edu

*Papers downloaded from **AgEcon Search** may be used for non-commercial purposes and personal study only. No other use, including posting to another Internet site, is permitted without permission from the copyright owner (not AgEcon Search), or as allowed under the provisions of Fair Use, U.S. Copyright Act, Title 17 U.S.C.*

J. Bangladesh Agril. Univ. 10(1): 69–77, 2012 **ISSN 1810-3030**

Gross and histological studies of digestive tract of broilers during postnatal growth and development

M. Nasrin, M. N. H. Siddiqi, M. A. Masum and M. A. Wares
Department of Anatomy and Histology, Bangladesh Agricultural University, Mymensingh-2202, Bangladesh
E-mail: mithundvm@yahoo.com

Abstract

We studied anatomy and histology of different segments of the digestive tract in postnatal growing broiler chickens with regard to their location, shape, size and weight. A group of four chickens, each at day 1 ($D_{1)}$, days 14 ($D_{14)}$ and days 28 ($D_{28)}$, total 12, were killed, their digestive tracts were dissected and described and shape, size and weight of different segments were recorded. Samples from different segments were prepared and stained with haematoxylin and eosin staining technique to study the histology under light microscope. The average lengths (cm) and weights (gm) of esophagus, proventriculus (glandular stomach), gizzard (muscular stomach), small intestine and large intestine were significantly higher ($P<0.01$) in chickens at D_{28} than that at D_{14} and at $D_{1.}$ The histological layers of digestive tract were lamina epithelia, lamina propria, lamina muscularis, submucosa, tunica muscularis and serosa with the exception in esophagus where outer adventitia was found. The esophageal glands were significantly more in numbers at D_1 (in cross section, 12 in number per focus under 100x) than at D_{14} (6 in number per focus under 100x) and at D_{28} (2 in number per focus under 100x). The proventriculus consisted of macroscopic papillae with numerous microscopic folds with lamina propria comprised of simple glands, which converged into a common cavity near the surface. In gizzard, the cuticle, in the form of wavy lines ran parallel to the surface. The villi of small intestine and large intestine were lined by simple columnar epithelium. The apical parts of villi of the duodenum were slightly pointed and the basal parts of the villi were thicker than jejunum and ileum, whereas, the villi of the jejunum and ileum became shorter and broader than duodenum and most of the villi had blunt apical part and the basal parts were wider. The numbers of goblet cells were numerous in number in ileum than duodenum and jejunum. Plicae ran along the inner surface of the distal two thirds of the cacea. However, in the colorectum, the villi appeared as numerous long flat leaf-shaped structures which filled a large proportion of the lumen. The average lengths and widths of villi of small and large intestine were significantly higher ($P<0.01$) in chickens at D_{28} than that at D_{14} and at $D_{1.}$ The number of goblet cells in lamina epithelium and intestinal glands of the lamina propria were numerous in number at D_{28} than the chickens at D_{14} and at $D_{1.}$

Keywords: Anatomy, Histology, Digestive tract, Postnatal growth, Broiler

Introduction

The digestive tract of chickens conveys food to the stomach: this system comprises, the crop, an expansion of the esophagus, located in the lower neck area, the glandular stomach (proventriculus), the muscular stomach (gizzard) and intestines. The length and weight of the small intestine varied between the different species of birds (Hassouna, E.M.A. *et al*., 2001). Differential development of the absorptive epithelium may be responsible for changes in absorption capacity of birds (Verdal *et al*., 2010). Available strains of broilers (eg. Cobb-500, cobb-700, arbor acress, lohman meat etc.) are the result of genetic modification. They grow fast with better feed conversion ratio (FCR) than any other indigenous variety of chicken. Histology of digestive tract of chickens were described by Aitken (1958); Calhoun (1954); Hassouna (2001). They did not provide data about morphology and histology of digestive tract of broilers in details. However, there was no report in Bangladesh regarding postnatal growth and development of digestive tract of broiler chickens. Therefore, the present study was conducted to describe anatomy (weight, length, size and shape) and histology of different segments of digestive tract of broilers in newly hatched and progressively matures broilers in Bangladesh that may be a basis for further study on nutritional modulation in the field of Veterinary science.

Materials and Methods

A total of twelve chickens (broilers), four chickens from each of 1 day, 14 days, and 28 days old groups were collected from poultry farm of Bangladesh Agricultural University (BAU), Mymensingh. All the chickens were reared in the Department of Anatomy and Histology with food and water *ad libitum*. After Cervical subluxation, the digestive tracts were collected for gross and histological study. The location,

shape, size, length, breadth and weight of the segments of digestive tract were considered for gross study. For histological study, small pieces of esophagus, proventriculus, gizzard, small intestine and large intestine were taken. These tissues were fixed in the “Bouins fluid” (Gridley, 1960) for 24 hours, dehydrated in the series of ascending grade of alcohol (70%, 80%, 90%, 95%, 100%), cleared in xylene, infiltrated in paraffin, embedded in paraffin and finally the paraffin blocks were sectioned at 6 µm thickness using sliding microtome (MIC 509, Euromex, Japan). After sectioning, the sections were floated on luke-warm water in a floatation bath for stretching and then the paraffin sections were mounted on slides using an egg albumin and dried on slide warmer. The sections were then stained with standard Haematoxylin and Eosin method (Gridley, 1960) for general microscopic study.

Results and Discussion

Anatomy of different segments of the digestive tract of broilers

Esophagus: The esophagus was a long, narrow and straight tube which extends from the glottis at the posterior end of the pharynx, through the neck and thorax to join with the glandular stomach. The average lengths of esophagus were 3.73±0.278 cm, 8.45±0.210 cm and 13.75±0.478 cm, at $D_{1,}$ D_{14} and D_{28} respectively (Fig. 9). The average weights of esophagus were 0.75±0.067 gm, 4.13±0.153 gm and 7.45±0.341 gm, at $D_{1,}$ D_{14} and D_{28} respectively (Fig. 10).

Proventriculus: The glandular stomach or proventriculus was relatively small and tubular. It was located caudal to the crop. The average lengths of proventriculus were 1.23±0.110 cm, 2.83±0.118 cm and 3.70±0.122 cm, at $D_{1,}$ D_{14} and D_{28} respectively (Fig. 9). The average weights of proventriculus were 0.48±0.042 gm, 2.88±0.268 gm and 6.25±0.028 gm, at $D_{1,}$ D_{14} and D_{28} respectively (Fig. 10).

Gizzard: The muscular stomach or gizzard was located immediately succeeding the proventriculus. It was placed partly between the lobes and partly behind the left lobe of the liver. It was built with thick strong muscles. The average lengths of gizzard were 1.825±0.018 cm, 3.275±0.112 cm and 5.32±0.128 cm, at $D_{1,}$ D_{14} and D_{28} respectively. The average weights of gizzard were 2.63±0.012 gm, 13.6±0.056 gm and 40.2±0.048 gm, at $D_{1,}$ D_{14} and D_{28} respectively.

Small intestine

Duodenum: The duodenum started at the gizzard and formed an elongated loop. After the duodenum, the small intestine formed a coil and was suspended from the dorsal abdominal wall the by a thin membrane – the mesentery. This membrane carried the blood vessels associated with the intestine. The average lengths of duodenum were 8.23±0.131 cm, 26.25±0.478 cm and 34.13±1.477 cm, at $D_{1,}$ D_{14} and D_{28} respectively (Fig. 9). This observation was similar with Hassouna (2001), where, the author stated that the length of the duodenal loop and its parts as well as its shape and extension varied in birds. The average weights of duodenum were 0.61±0.029 gm, 6.53±0.348 gm and 13.02±1.361 gm, at $D_{1,}$ D_{14} and D_{28} respectively (Fig. 10).

Jejunum: There was no clear demarcation between the jejunum and ileum. Meckel’s Diverticulum was a constant feature about half way along the small intestine appearing as a small projection on the outer surface of the small intestine. This projection was where the yolk stalk attached during the development of the embryo. The average lengths of jejunum were 22.38±0.625 cm, 68.25±0.629 cm and 123.50±3.663 cm, at $D_{1,}$ D_{14} and D_{28} respectively. This observation was similar with Hassouna (2001), where, the author stated that in all bird species the jejunum was the longest part of the small intestine. The average weights of jejunum were 0.823±0.032 gm, 7.56±0.112 gm and 46.53±0.242 gm, at $D_{1,}$ D_{14} and D_{28} respectively.

Ileum: The average lengths of ileum were 6.6±0.625 cm, 22.5±0.629 cm and 31±3.663 cm, at $D_{1,}$ D_{14} and D_{28} respectively (Fig. 9). This observation was similar with Hassouna (2001), where, the author found that lowest mean percentage of the length of ileum to the total length of the small intestine in chicken (2.7%). The average weights of ileum were 0.32±0.043 gm, 2.65±0.217 gm and 11.75±0.882 gm, at $D_{1,}$ D_{14} and D_{28} respectively (Fig. 10).

Large intestine

Caeca: The large intestine started from the caeca, and the two caeca were blind pouches and extend along the line of the small intestine towards the liver having proximal and distal part, and were closely attached to the small intestine along their length by the mesentery. Each caecum had three main parts. This observation was similar with Hassouna (2001), where, the author proved that caeca were long cylindrical expansions in chickens. The average lengths of each caeca were 3.625±0.217 cm, 10.25±0.645 cm and 18.125±1.732 cm, at $D_{1,}$ D_{14} and D_{28} respectively (Fig. 9). The average weights of caeca were 0.15±0.035 gm, 1.99±0.143 gm and 5.53±0.787 gm, at $D_{1,}$ D_{14} and D_{28} respectively (Fig.10).

Colorectum: It was the terminal part of the intestine, passing between the ileo-cecal junction and the cloaca. It was comparatively short and straight and had thick, muscular walls. The average lengths of colorecti were 2.925±0.119 cm, 6.82±0.011 cm and 8.83±0.037 cm, at $D_{1,}$ D_{14} and D_{28} respectively. The average weights of colorecti were 0.48±0.022 gm, 1.95±0.212 gm and 4.66±0.018 gm, at $D_{1,}$ D_{14} and D_{28} respectively.

Histology of different segments of the digestive tract of broilers

Esophagus: The esophageal wall of the chicken studied was consisted of lamina epithelia, lamina propria, lamina muscularis, submucosa, tunica muscularis and tunica adventitia (Fig. 1). The lining epithelium of the esophagus was nonkeratinized stratified squamous epithelium which was thicker in the chickens of D_{28} than at D_{14} and at $D_{1.}$ The mucosal types of glandular cells were located in the lamina propria of the esophagus. In this study esophageal glands were significantly more in numbers at D_1 (in cross section, 12 in number per focus under 100x) than at D_{14} (6 in number per focus under 100x) and at D_{28} (2 in number per focus under 100x).

Proventriculus: The proventriculus of glandular stomach of chicken was consisted of macroscopic papillae with numerous microscopic folds. Simple single glands grouped to form lobules each of which converged into a common cavity near the surface. The cavities converged to form a common duct that lead to the surface through the apex of a small papilla. The surface epithelium on the folds was a simple columnar tissue, and each fold had a core of lamina propria to support it. This observation was similar to the result made by Aitken (1958), where, the author reported that the mucosa contains simple tubular glands lined throughout their length by a columnar epithelium. The wall of glandular stomach was very thick and consisted of several layers i.e. inner mucosal membrane, submucosa, tunica muscularis and outer serosa (Fig. 3). The submucosal glands formed the greater part of the thickness of the organ.

Gizzard: The gizzard was a highly muscular organ responsible for grinding and macerating the ingesta. Cuticle looked like pattern of wavy lines running parallel to the surface (Fig. 4). Attempts were made to characterize chemically the cuticular layer of the gizzard, although the majority of authors referred to it as “horny” and appeared to consider that it was a keratinous substance. Aitken, (1958), considered it as horny material. Bradley & Grahame (1950), on the other hand, considered this material as keratohyalin, but did not indicate on which reactions this claim was based. Calhoun (1954) also considered the horny material as keratohyalin, based on the results of a single reaction. The surface epithelium was simple columnar tissue but branched tubular mucosal glands were simple cuboidal. This finding was similar to the results made by Aitken, (1958), where the author stated that in the gizzard the glands were simple uncoiled tubules lined throughout the greater part of their length by low cuboidal cells and columnar cells covering the free surface. The lamina propria and submucosa consisted of loose connective tissue. The tunica muscularis were strongly thick and consisted of parallel smooth muscle and outer serosa.

Small intestine

Duodenum: The villi of the duodenum of chicken studied were lined by simple columnar epithelium. This observation was similar with Aitken (1958), where, the author stated that in small intestine, the surface epithelium was simple columnar. The apical parts of villi of the duodenum were slightly pointed and the basal parts of the villi were wider (Fig. 5). The average lengths of villi of duodenum were 280.0 ± 1.080

µm, 507.55±1.022 µm and 870.75±2.287 µm, at D_1, D_{14} and D_{28} respectively (Fig. 11). The average widths of villi of duodenum were 72.5±0.354 µm, 101.75±0.362 µm and 123.25±0.629 µm, at D_1, D_{14} and D_{28} respectively (Fig.12). The numbers of goblet cells were more at D_{28} than that at D_{14} and at D_1. In the lamina propria, intestinal glands of tubular shaped and lymphatic nodules were abundant at D_{28} than that at D_{14} and D_1. Lymph nodules occured in the lamina propria of the duodenum increased with ages. Brunner's glands and Paneth cells were not present in duodenum. This observation was similar with Aitken (1958), where, the author reported that no Brunner's glands and Paneth cells were present in duodenum.

Jejunum: The villi of the jejunum of chicken studied were lined by simple columnar epithelium, which were shorter and broader than that in duodenum. Most of the villi had blunt apical part and wide basal part. The average lengths of villi of jejunum were 362.55±1.093 µm, 536.525±1.676 µm and 652.625±1.700 µm, at D_1, D_{14} and D_{28} respectively (Fig. 11). The average widths of villi of jejunum were 72.625±1.028 µm, 94.3625±0.618 µm and 108.187±51.096 µm, at D_1, D_{14} and D_{28} respectively (Fig. 12). The numbers of goblet cells in lamina epithelium and intestinal glands in the lamina propia were more at D_{28} than that at D_{14} and at D_1.

Ileum: The lining epithelium was same to duodenum and jejunum. Most of the villi had blunt apical part and wide basal part (Fig. 6). The average lengths of villi of ileum were 174.0±0.408 µm, 594.375±2.095 µm and 1161±4.203 µm, at D_1, D_{14} and D_{28} respectively (Fig. 11). The average widths of villi of ileum were 36.3125±0.850 µm, 79.3125±0.449 µm and 137.9375±0.819 µm, at D_1, D_{14} and D_{28} respectively (Fig. 12). The numbers of goblet cells were more in ileum than that in duodenum and jejunum. This observation was similar with Aitken (1958), who reported that goblet cells apparently more in number as the gut is traced caudally. In the lamina propria, intestinal glands decreased considerably. However, they were more abundant at D_{28} than that at D_{14} and D_1.

Large intestine

Caeca: Plicae were well-developed folds of mucous membrane and muscularis mucosae which ran along the inner surface of the distal two thirds of the caeca (Fig.7). The average lengths of villi of caecum were 232.25±1.181 µm, 507.875±1.087 µm and 870±2.273 µm, at D_1, D_{14} and D_{28} respectively (Fig. 11). The average widths of villi of caecum were 101.75±0.722 µm, 246.5625±1.209 µm and 464.25±0.853 µm, at D_1, D_{14} and D_{28} respectively (Fig. 12).

Colorectum: The mucosal folds appeared as numerous long flat leaf-shaped structures which filled a large proportion of the lumen (Fig. 8). The average lengths of villi of colorectum were 217.875±0.826 µm, 667.75±3.092 µm and 1087.875±2.276 µm, at D_1, D_{14} and D_{28} respectively (Fig. 11). The average widths of villi of colorectum were 87.75±0.854 µm, 304.625±1.841 µm and 652.73±2.429 µm, at D_1, D_{14} and D_{28} respectively (Fig. 12).

The CRD (Complete Randomized Design) test for comparasion and development of size of villi showed that the length of villi of duodenum, jejunum, ileum, cecum and colorectum among and within the groups were significant at D_{28} ($P<0.01$) than that at D_{14} and at D_1. The width of duodenum, jejunum, ileum among and within the groups were significant ($P<0.05$) and highly significant ($P<0.01$) in cecum and colorectum at D_{28} than that at D_{14} and at D_1.

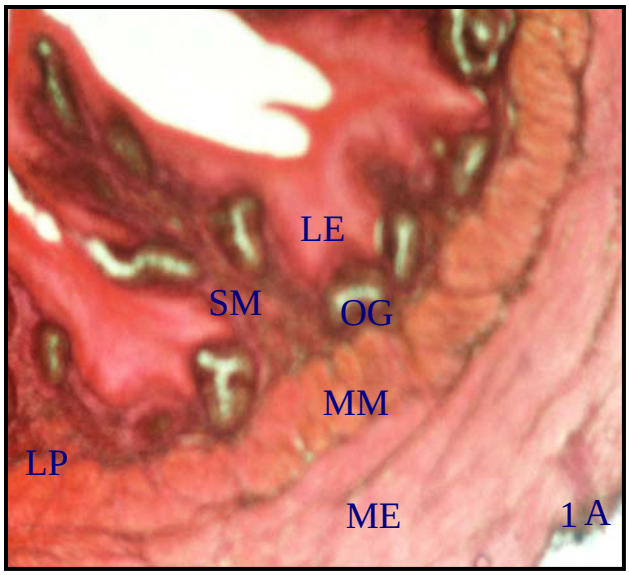

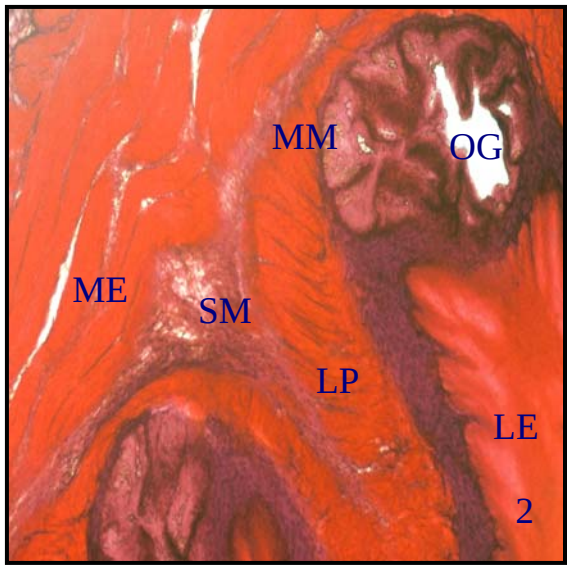

Fig.1& 2. Histology of esophagus at day-old chicken (Fig. 1) and D_{28} (Fig. 2). Here, Lamina epithelia (LE), Lamina propria (LP) Oesophageal gland (OG), Muscularis mucosae (MM), Submucosa (SM), Muscularis externa (ME) and adventitia (A) are shown. H & E × 100

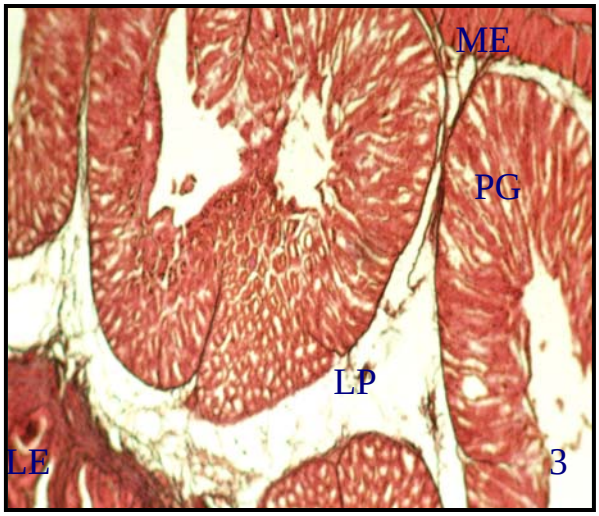

Fig 3. Histology of proventriculus at day-old chicken. Here, Lamina epithelia (LE), Lamina propria (LP) containing strands of muscularis mucosae, Proventricular gland (PG) and Muscularis externa (ME) are shown. H & E × 100

Fig 4. Histology of gizzard at day-old chicken. Here, Cuticle(C), Glands (G) are shown. H & E × 100

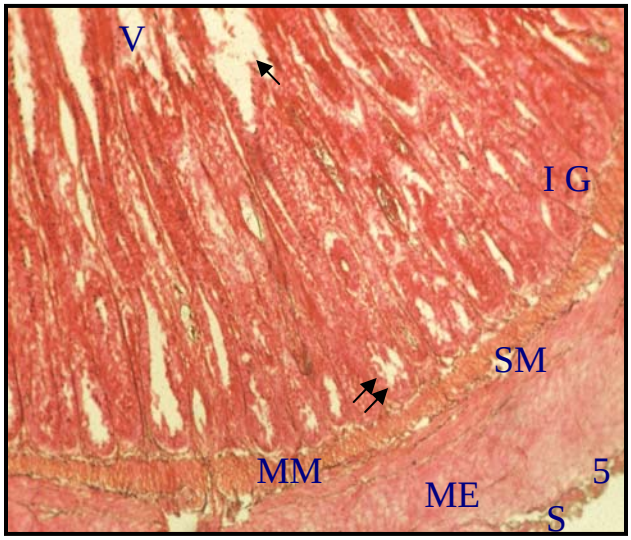

Fig. 5. Histology of Duodenum of the chickens at D_{28}. Here, Villi (V), Intestinal gland (IG), Muscularis mucosae (MM), Muscularis externa (ME) and Serosa (S) are shown. Apical point of villi is pointed (single arrow), basal part is wider (double arrow). H & E ×100

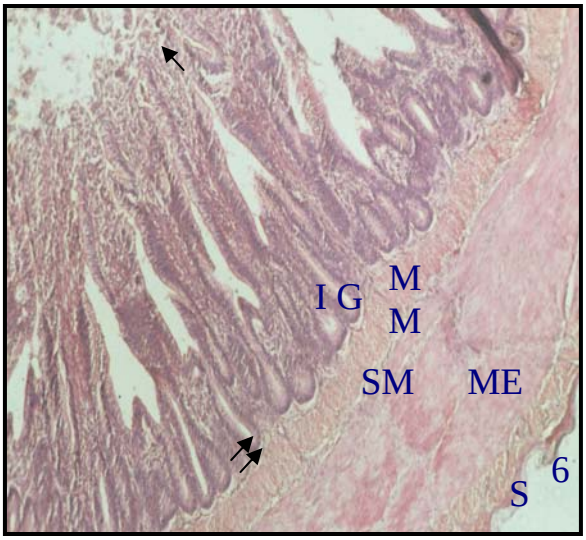

Fig. 6. Histology of Ileum of the chickens at D_{14}. Here, Villi (V), Intestinal gland (IG), Muscularis mucosae (MM), Muscularis externa (ME) and Serosa (S) are shown. Apical point of villi is blunt (single arrow), basal part is wider (double arrow). H & E ×100.

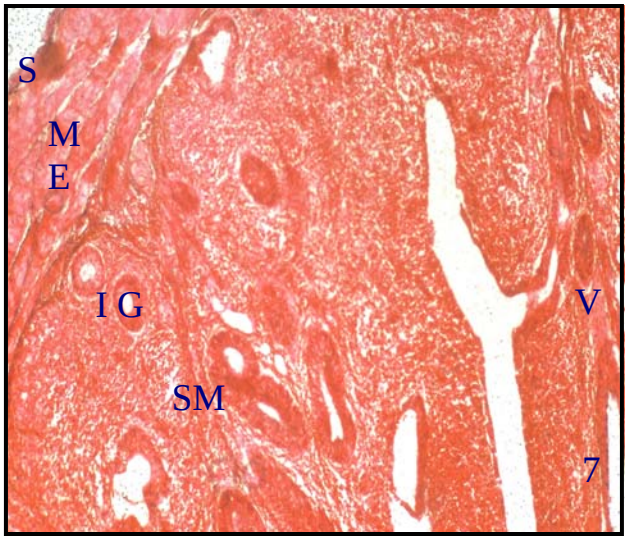

Fig. 7. Histology of cecum of the chickens at D_{28}. Here, Villi (V), Intestinal gland (IG), Submucosa (SM), Muscularis externa (ME) and Serosa (S) are shown. H & E ×100.

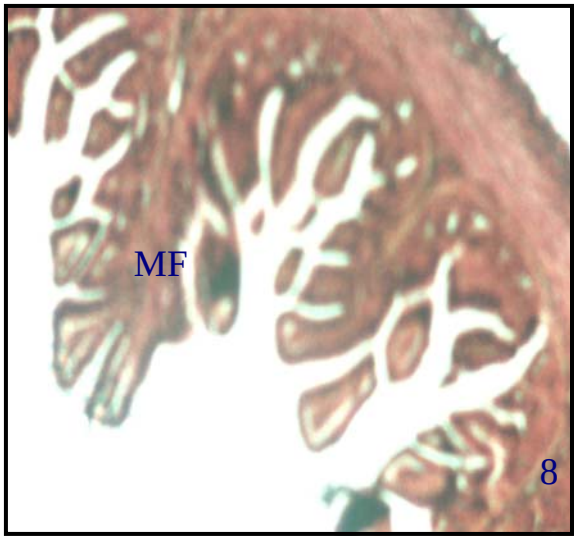

Fig. 8. Histology of colorectum of day-old chickens. Here, Mucosal folds (MF) are shown. H & E ×100.

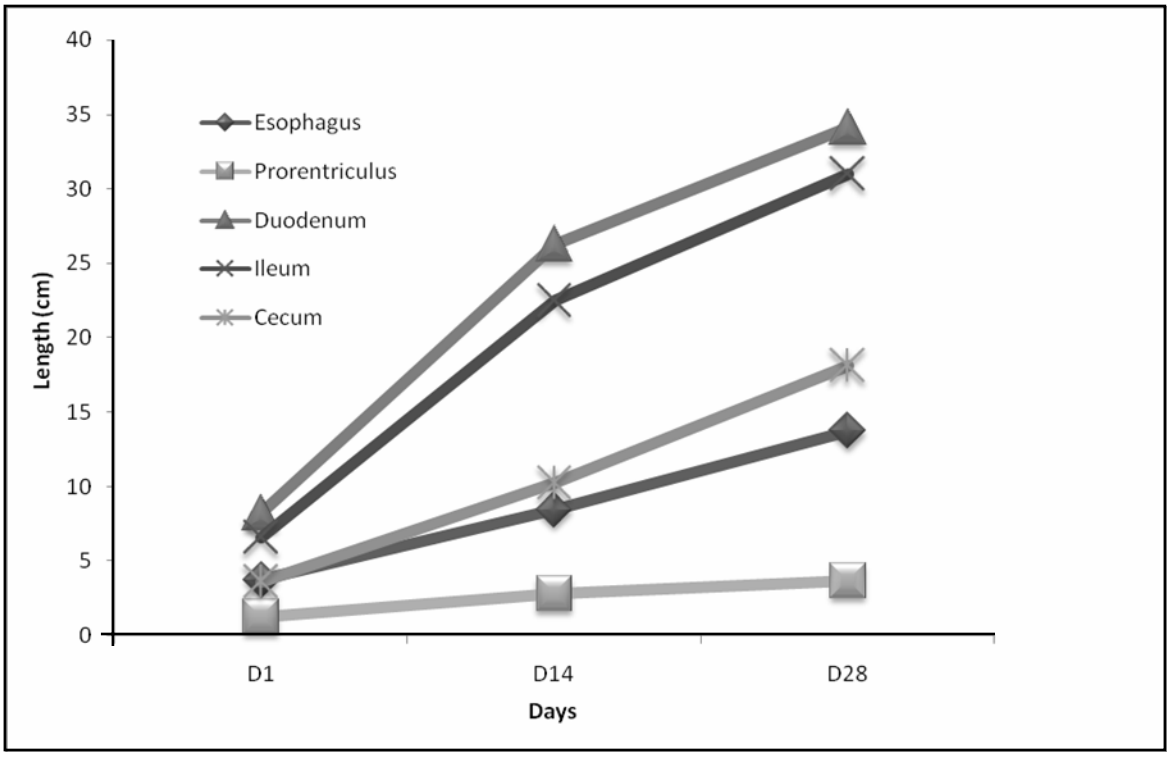

Fig. 9. Comparasion of the length (cm) of esophagus, proventriculus, duodenum, ileum and cecum during postnatal growth from D_1 to D_{28}.

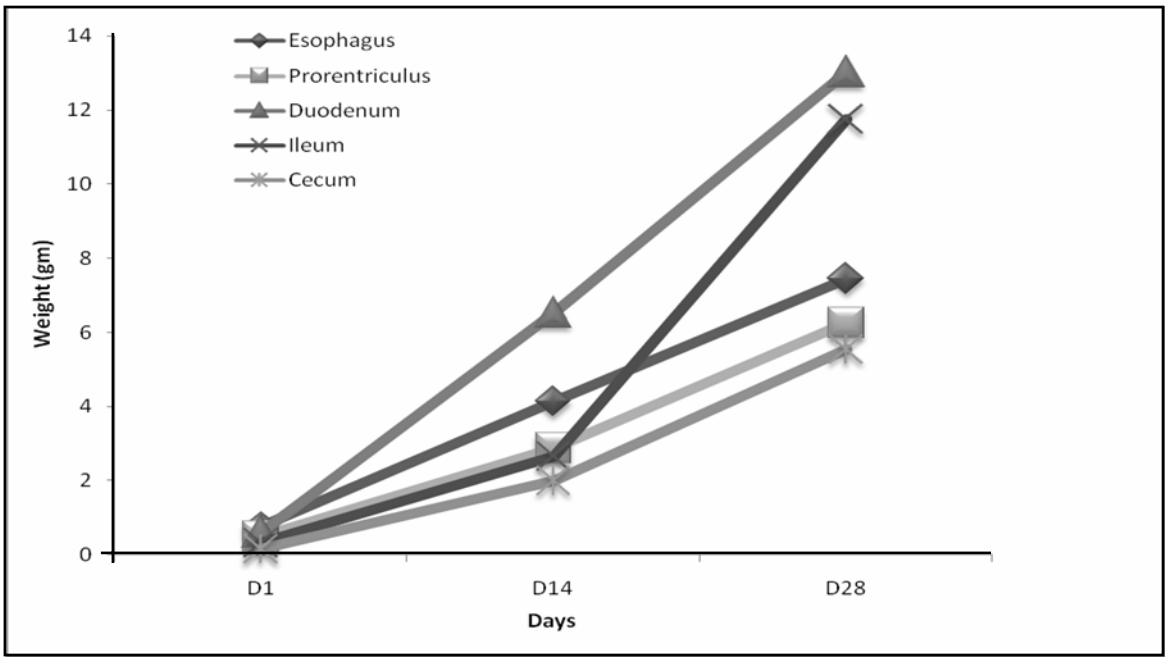

Fig. 10. Comparasion of the weight (g) of esophagus, proventriculus, duodenum, ileum and cecum during postnatal growth from D_1 to D_{28}

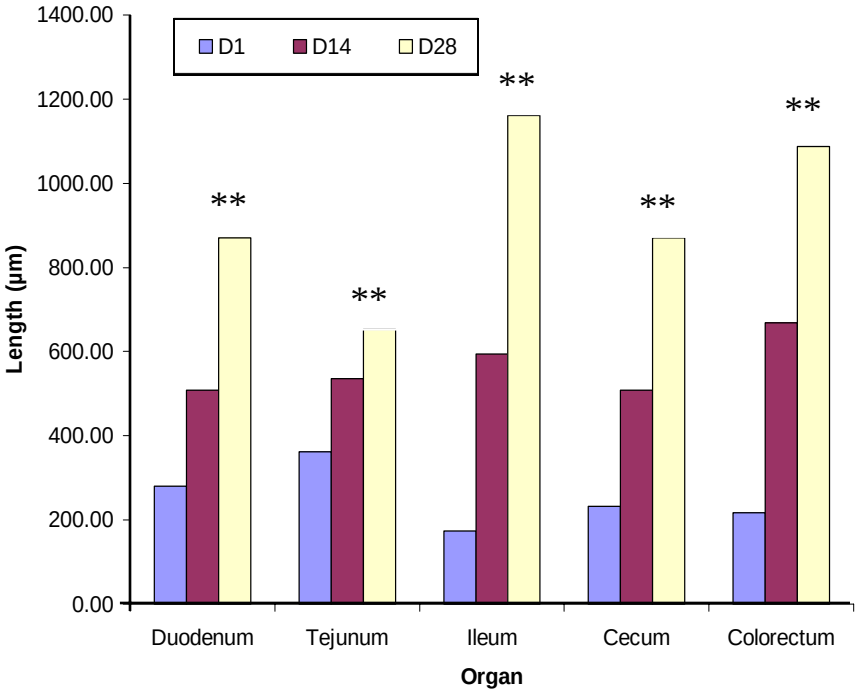

Fig. 11. Comparasion and development of length (µm) of villi of duodenum, jejunum, ileum, cecum and colorectum during postnatal growth from D_1 to D_{28}.

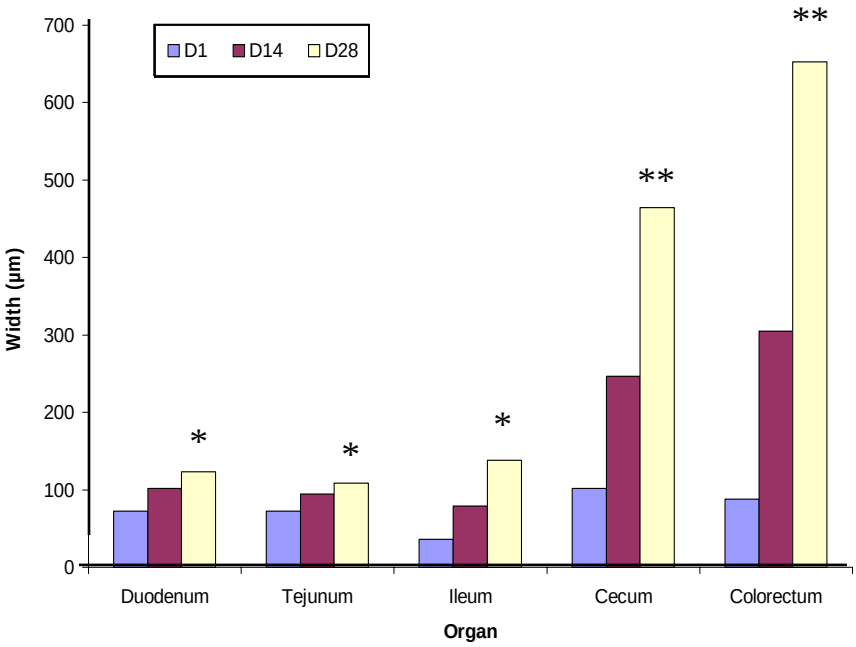

Fig. 12. Comparasion and development of width (µm) of villi of duodenum, jejunum, ileum, cecum and colorectum during postnatal growth from D_1 to D_{28}.

* = significant at 5% of probability , ** = significant at 1% of probability

Conclusion

The average lengths and weights of esophagus, proventriculus, gizzard, small intestine and large intestine were significantly higher ($P<0.01$) at D_{28} than that at D_{14} and at $D_{1.}$ Various layers of digestive tract were lamina epithelia, lamina propria, lamina muscularis, submucosa, tunica muscularis and serosa except in esophagus where outer adventitia was found. Esophageal glands were significantly more in numbers at D_1 than that at D_{14} and at D_{28}. The average lengths and widths of villi of small and large intestine were higher at D_{28} than that at D_{14} and at $D_{1.}$ The villi became shorter and broader and the depths of intestinal gland decreased considerably in ileum than that of duodenum and jejunum. The numbers of goblet cells increased in ileum than that of duodenum and jejunum with the advancement of age.

References

Aitken, R.N.C. 1958. A histochemical study of the stomach and intestine of the chicken. *Journal of Anatomy,* 453-466.

Bradley, O.C. and GraHame, T. 1950. The structure of the fowl. *Pathology* 35, 12-32.

Calhoun, M. Lois. 1954. Microscopic anatomy of the digestive system of the chicken. *Ames, Iowa: Iowa State Colleage Press.*

Gridley, M.F. 1960. Manual of histologic and special staining technique. *MacGraw-Hill Book Company*, 28-29, 82-83.

Hassouna, E.M.A. 2001. Some anatomical and morphometrical studies on the intestinal tract of chicken, duck, goose, turkey, pigeon, dove, quail, sparrow, heron, jackdaw, hoopoe, kestrel and owl. *Assiut Veterinary Medical Journal.* 44: 47-78.

Verdal, H. de, Mignon-Grasteau, S., Jeulin, C., Bihan-Duval, E. Le, Leconte, M., Mallet, S., Martin, C. and Narcy, A. 2010. Digestive tract measurements and histological adaptation in broiler lines divergently selected for digestive efficiency. *Poultry Science.* 89: 1955-1961.