



AgEcon SEARCH
RESEARCH IN AGRICULTURAL & APPLIED ECONOMICS

The World's Largest Open Access Agricultural & Applied Economics Digital Library

This document is discoverable and free to researchers across the globe due to the work of AgEcon Search.

Help ensure our sustainability.

Give to AgEcon Search

AgEcon Search
<http://ageconsearch.umn.edu>
aesearch@umn.edu

*Papers downloaded from **AgEcon Search** may be used for non-commercial purposes and personal study only. No other use, including posting to another Internet site, is permitted without permission from the copyright owner (not AgEcon Search), or as allowed under the provisions of Fair Use, U.S. Copyright Act, Title 17 U.S.C.*

TB 49 (1928)
NEMATODES OF PATHOLOGICAL SIGNIFICANCE FOUND IN SOME ECONOMICALLY
CRAM. E. B.


USDA TECHNICAL BULLETINS

1


UPDATA

1 OF 1

START



MICROCOPY RESOLUTION TEST CHART
NATIONAL BUREAU OF STANDARDS-1961-A



MICROCOPY RESOLUTION TEST CHART
NATIONAL BUREAU OF STANDARDS-1963-A

UNITED STATES DEPARTMENT OF AGRICULTURE
 WASHINGTON, D. C.

 NEMATODES OF PATHOLOGICAL SIGNIFICANCE
 FOUND IN SOME ECONOMICALLY IMPORTANT
 BIRDS IN NORTH AMERICA¹

BY ELOISE B. CRAM

Associate Zoologist, Zoological Division, Bureau of Animal Industry

CONTENTS

	Page		Page
<i>Capillaria annulata</i> in chickens and turkeys.....	1	Echinuria in wild ducks and geese.....	4
Strongyle infestation of domesticated geese.....	2	Gapeworm infestation of wild geese.....	6
Nematodes found in pigeons and other birds.....	3	Conclusion.....	9
		Literature cited.....	9

During the past year and a half the writer has been impressed with the considerable number of nematodes of pathological significance which are found in this country in either domesticated fowls or other birds of economic importance. Although some of these parasites have been reported individually at the time of the finding, it is considered worth while to bring together and summarize former reports with the new ones, that a more general idea may be formed of the part played by parasitic nematodes in the production of pathological conditions in poultry and other economically important birds of this country.

CAPILLARIA ANNULATA IN CHICKENS AND TURKEYS

During the last two autumns there was found, first in turkeys (4)² and more recently in chickens in Maryland, a parasite previously unknown in this country, which to all appearances is of marked pathological significance. This nematode, *Capillaria annulata* (fig. 1), very slender and threadlike, as capillarids usually are, is sewed into the mucosa of the esophagus, including the crop. In the early stages a hyperemia and the blocking and enlargement of the lymph follicles are apparent; the walls of the parasitized parts become greatly thickened and nonelastic; in later stages a sloughing of the mucosa and the formation of a fibrinous pseudomembrane

¹ Read in part at the second annual meeting of the American Society of Parasitologists, Dec. 30, 1926, in Philadelphia, Pa.

² Italic numbers in parentheses refer to "Literature cited," p. 9.

occur. A study of the microscopic changes of the tissues in material collected by the writer has been made by Hung (6). The thickening and loss of elasticity of the affected parts and the impairment of the lymphatic apparatus must certainly lower the efficiency of this part of the digestive tract, and the loss of appetite and the weakened, emaciated condition seen in chickens and turkeys harboring this parasite, resulting finally in their death, may be ascribed partially, if not wholly, to infestation with this nematode. The pseudomembrane, sometimes 1.5 mm. thick, undoubtedly interferes with the functioning of the crop, and birds showing this pseudomembrane have a

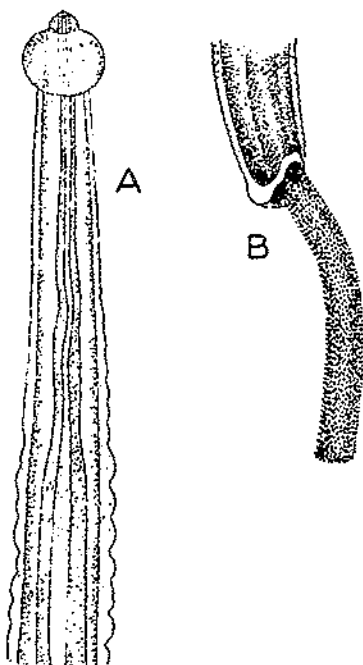


FIG. 1.—*Capillaria annulata*—A, head end; B, male tail; after Clurea, 1914

history of having rejected grain and eaten only soft feeds. In Europe *C. annulata* occurs in chickens and is apparently not reported as impairing their health; it also occurs in pheasants, in which it has been reported as having proved fatal, the symptoms being similar to those found in chickens and turkeys in this country. It has been identified by the writer in the ruffed grouse of Michigan and should therefore be kept in mind in the study of diseases affecting that bird. The parasite is apparently widespread in this country; in a recent survey it has been found in chickens in Georgia, Mississippi, and Louisiana, the lesions being the same as those described above.

STRONGYLE INFESTATION OF DOMESTICATED GESE

Another disease new to this country was found during 1926 (3) among domestic geese in the form of infestation of the gizzards with a strongyle, *Amidostomum anseris*. (Fig. 2.) The deaths of large

numbers of geese in New York were apparently due to the parasite. Recently this nematode has been identified from wild geese in Canada (vicinity of Ottawa), the writer being indebted to A. B. Wickware for the material. Geese heavily infested with *A. anseris* lose appetite and become emaciated and anemic; the gizzards display a crumbling, necrotic, horny lining with deposits of brown pigment, evidently the result of hemorrhages, and throughout this lining the nematodes are found in large numbers, the head usually buried in the tissue. This disease, known as "Magenwurmseuche" in Germany, has been regarded as the cause of death among domestic geese in that country and elsewhere in Europe, and its pathology has been studied by Joest (7). Bunyea and Creech (1), of the Bureau of Animal Industry, made a histopathological study of infested gizzards collected by the writer. Of special interest was their finding of a marked local eosinophilia in the mucosa propria of the gizzard.

NEMATODES FOUND IN PIGEONS AND OTHER BIRDS

Among carrier pigeons of the Signal Corps of the United States Army, heavy infestations of the proventriculus with *Dispharynx spiralis* (fig. 3) have caused the death of many of the birds. Through the courtesy of C. C. Whitney, Fort Sam Houston, Tex., the writer was supplied with the proventriculus of one of these birds, in order to identify the parasite and study the changes. The symptoms of infestation, as described in correspondence by Whitney, are droopiness and loss of weight by the birds, which, however, retain a ravenous appetite even up to the time of death. Loss of pigmentation of the iris, probably due to anemia produced by the worms, is also a

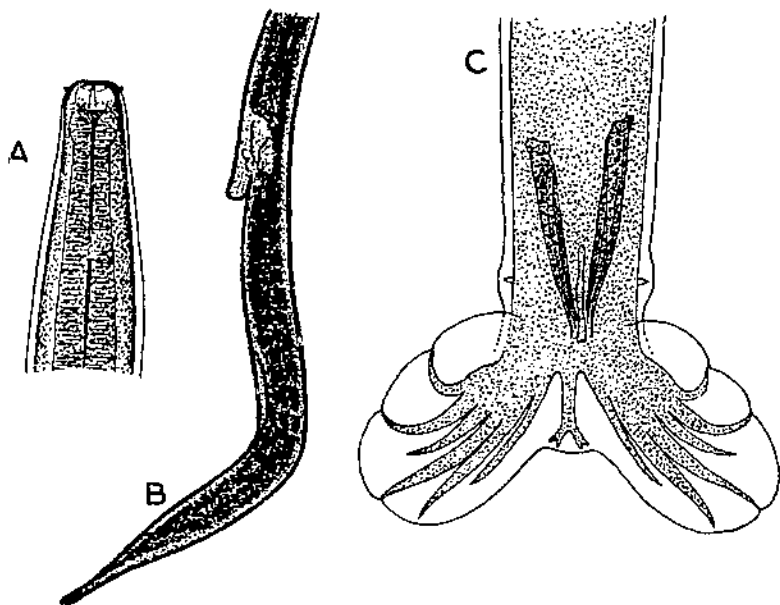


FIG. 2.—*Amidostomum anseria*.—A, head end; after Railliet, 1893. B, vulva and tail of female; after Reinhardt, 1922. C, male tail; after Railliet, 1893

marked feature associated with the disease. That the birds never lose their appetites has been noted by previous writers in connection with a similar disease of chickens, caused by a closely related species, *D. nasuta*; this nematode, when present in large numbers, may produce cachexia and death of the birds. In the case mentioned, the proventriculus of the pigeon was greatly enlarged and macroscopically had lost all its normal appearance of a glandular organ, the inner surface being a thick, necrotic mass containing large numbers of the nematode *D. spiralis*. Microscopically there appeared to be almost complete destruction of the glands and a marked cellular infiltration of the underlying tissue.

This same nematode, *D. spiralis*, is found also in the chicken, guinea fowl, and pheasant, and has been reported for the first time, by the writer, from the ruffed grouse and the turkey.

A parasitic disease of pigeons which was described many years ago by Stevenson (8) as the probable cause of death of large numbers of the birds in Washington, D. C., has been found again recently in the same city. The nematode, *Ornithostrongylus quadriradiatus* (fig. 4), occurred in this case, as formerly, in large numbers in the small intestine of the bird. The digestive tract of the worms, when they were collected, was bright red from ingested blood, the loss of blood by the birds undoubtedly being an important factor in the debilitating effect which these parasites have on the bird. A closely related nematode, *Trichostrongylus pergracilis*, was reported for the first

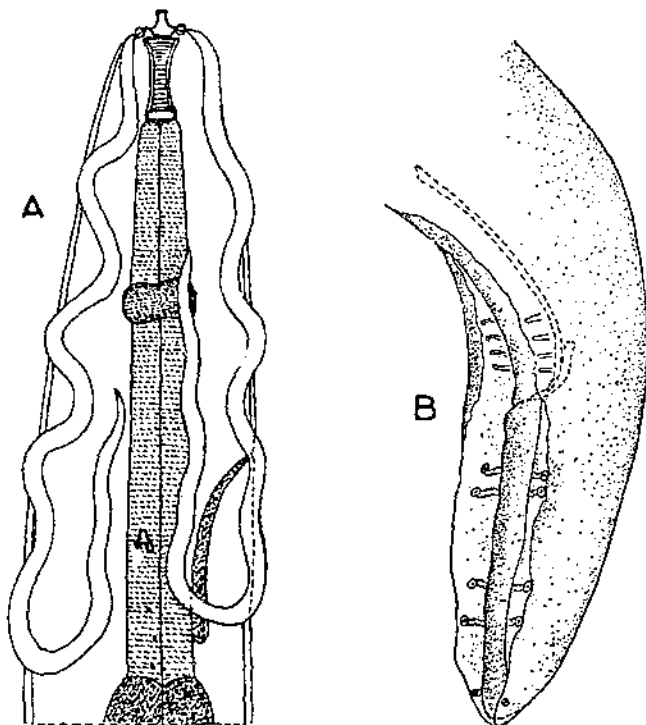


FIG. 3.—*Dispharynx spiralis*. A, head end; after Seurat, 1917. B, male tail; original

time in this country in 1926 from the quail (*Colinus virginianus*), from Georgia. The death of large numbers of red grouse (*Lagopus scoticus*) has been attributed to this parasite in England, so that it may possibly be of pathological importance among the quail of this country.

ECHINURIA IN WILD DUCKS AND GEESE

A spirurid, *Echinuria uncinata*, the reports of which had formerly been limited to Europe and Africa, has been found in this country in the black duck (*Anas rubripes*) of New York State, and in green-winged teals (*Nettion carolinense*) of Idaho. This nematode may occur in the esophagus, proventriculus, gizzard, or small intestine,

the worms lying in nodules which have a caseous content and which may become so large, especially in the proventriculus or gizzard, as to occlude the lumen and prevent the passage of food. In Europe infestation with this worm in the domestic duck, goose, and swan has been described as producing droopiness, the plumage becoming ruffled, and swallowing becoming difficult or impossible. After death, which may occur suddenly, the infested organs show a pronounced inflammation.

Recently a new species of *Echinuria* has been found in large numbers in the proventriculus of a wild goose (probably *Branta canadensis*) in Ottawa, Canada, the material being submitted by A. B. Wickware. The name *Echinuria parva* is here proposed for this nematode to indicate a marked characteristic of the nematode, its unusually small size, the males being 4 mm., gravid females from 6

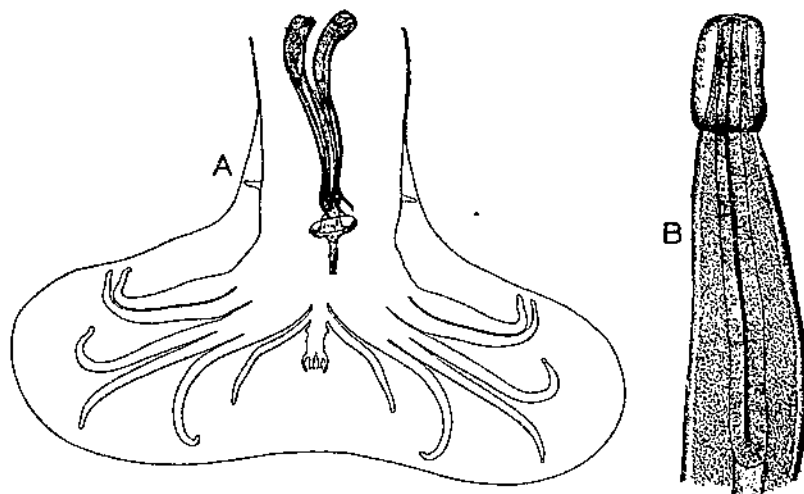


FIG. 4.—*Ornithostrongylus quadriradiatus*. A, male tail; B, head end; after Stevenson, 1904

to 6.8 mm., long. In *E. uncinata*, mentioned above as found in wild ducks in this country, the males are from 8 to 10 mm. long, and the females from 12 to 19 mm. Other diagnostic points which establish the form from the goose as a new species are the following:

Cordons (fig. 5) short but relatively longer than in *E. uncinata*, being in the male, one-twelfth, in the female one-ninth, of the total body length, whereas in *E. uncinata* they are one-sixteenth of the total body length in both sexes. Total length of esophagus, one-third of body length; cervical papillae very small, situated at about the anterior quarter or third of the length of the cordons at the level of the origin of the double rows of spines, at which point the cordon forms a ventral curve, the papilla lying close to the cordon. In the male the spines become very small and gradually disappear about 850 μ from the posterior end of body; in the female they are apparent to within 25 μ of the posterior end of body. Anus of female 140 to 180 μ from tip of tail; vulva in posterior part of body, dividing body length in ratio of 7½:1. Spicules of male unequal and dissimilar, the one 680 μ long by 17 μ wide, the other 216 μ long by 42 μ wide; cloacal aperture about 250 μ from posterior end of body; a total of 16 caudal papillae (fig. 5), the 8 postanal arranged as 4 pairs along the lateral fields, the 8 preanal arranged as 2 pairs of double papillae.

These characters distinguish this species from any of the 13 previously described species of *Echinuria* found in birds; a key to and descriptions of the 13 earlier species have been given by the writer (5). This new species is of marked pathological significance, as are some other species of the genus, the mucosa of the proventriculus (fig 6) in infested birds being almost completely covered with ulcers and fairly bristling with the slender, colorless worms, their heads embedded, their tails protruding into the lumen.

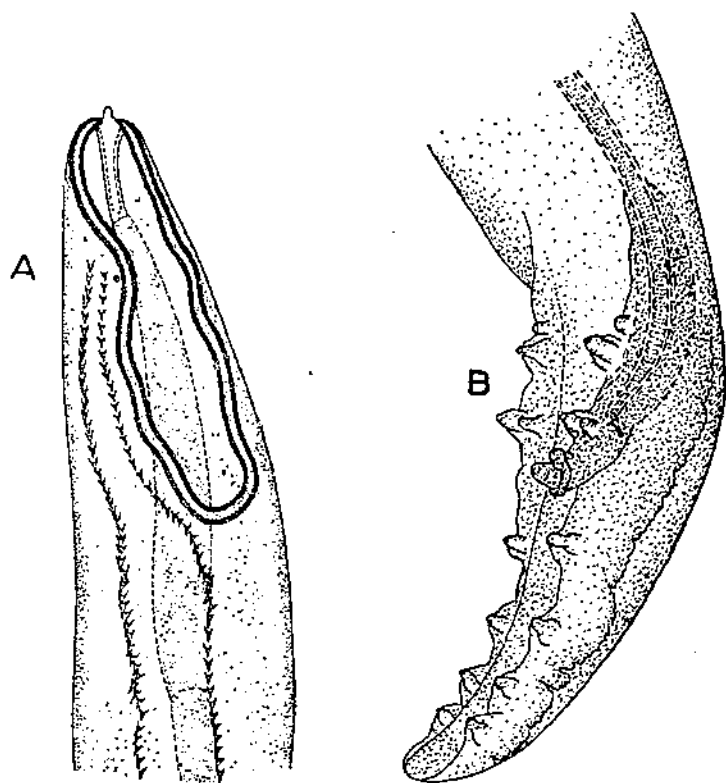


FIG. 5.—*Echinuria parva*. A, head end; B, male tail; original

GAPEWORM INFESTATION OF WILD GEESE

A third instance of parasitosis of geese is gapeworm infestation which has been fatal to numerous young birds which were being raised in captivity in north-central Illinois. Young blue, cackling, snow, and Canada geese from 10 days to 4 weeks of age were killed by numerous gapeworms in the trachea. Adult geese showed no evidence of the disease; young birds which survived appeared to overcome the infection when about half grown. Large numbers of chickens, turkeys, and wild ducks of several varieties (mallards, pintails, black ducks, and wood ducks) ranged largely over the same ground as the young geese, but none ever showed evidence of harboring gapeworms,

so that the parasite has a very restricted host range, only the wild geese being involved. Examination of the trachea of one of the young Canada geese (*Branta canadensis*) revealed what appears to be a new species of *Cyathostoma*, for which the name *Cyathostoma*

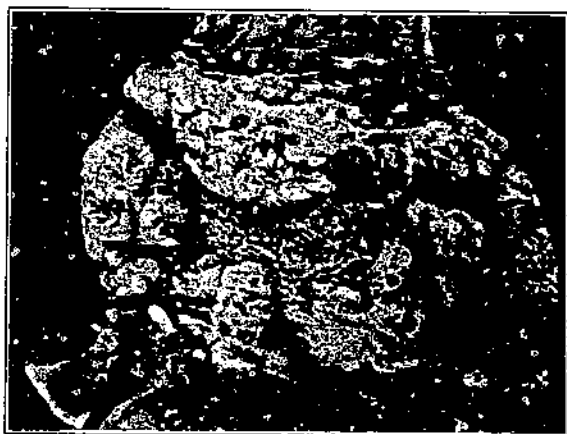

FIG. 6.—Lesions produced by *Echinuria parva* in proventriculus of goose

brantae is here proposed. The diagnostic characters of this nematode are as follows: Head with six large papillae which coalesce to form an inflated collar exterior to the mouth opening. (Fig. 7.) Buccal capsule with thick walls and provided at the base with seven teeth.

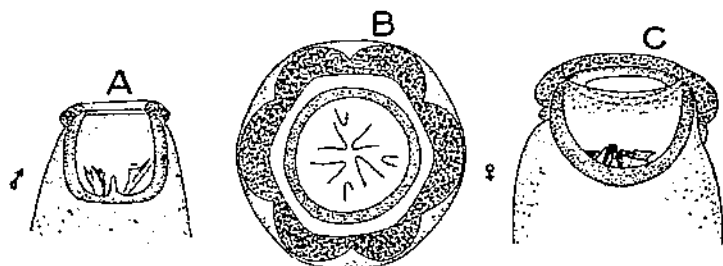


FIG. 7.—*Cyathostoma brantae*. A, head end of male, side view; B, front view of female; C, side view of female; original

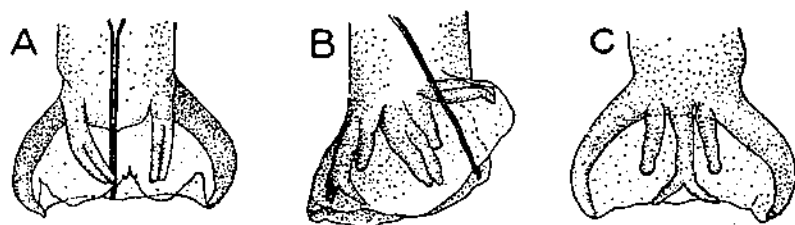
Table 1 gives the measurements of *C. brantae* as compared with *C. americanum*, the only other species found up to the present time, at least in any numbers,³ in this country and to which species *C. brantae* is most closely related.

³ Chapin (2) has reported that a single female specimen of *Cyathostoma* from a swan at Ithaca, N. Y., resembles *C. bronchialis*.

TABLE 1.—Comparative measurements of the nematodes, *Cyathostoma americanum* and *C. brantae*

MALE								
Species	Length	Buccal capsule			Size of teeth	Esophagus	Spicules	Gubernaculum
		Depth	Internal diameter	Wall thickness				
<i>C. americanum</i>	Mm. 12	μ 170	μ 185	μ 25	57 (μ largest).	730 long; 74 μ in least, 130 in greatest, diameter.	470 μ to 400	μ 67
<i>C. brantae</i>	8 to 9	108	91	17	42 (largest), 33 (smallest).	664 long; 100 in least, 183 in greatest, diameter.	604	85 to 95

FEMALE								
Species	Length	Buccal capsule			Size of teeth	Esophagus	Vulva	Eggs
		Depth	Internal diameter	Wall thickness				
<i>C. americanum</i>	Mm. 30	μ 280	μ 370	μ 20	60 (μ largest).	960 long; 130 in least, 250 in greatest diameter.	Just anterior to middle of body. At anterior third.	Not given. μ 72X 42
<i>C. brantae</i>	22 to 25	200	266	33	50 (largest), 40 (smallest).	1.1 to 1.2 long; 123 in least, 258 in greatest, diameter.	250 to 266 from end.	79X 50

¹ Millimeters.Hosts.—*C. americanum*: *Buteo borealis*.*C. brantae*: *Branta canadensis*, *B. canadensis minima*, *Chen caerulescens*, and *C. hyperboreus*.An examination of cotype specimens of *Cyathostoma americanum*, which is a parasite of the red-tailed hawk, *Buteo borealis*, showed unmistakable differences between it and *C. brantae* from the goose.FIG. 8.—*Cyathostoma brantae*. A, male tail, ventral view; B, lateral view; C, dorsal view; original

The position and character of the vulva of the new species are the most notable features of the female; the vulva is situated at the anterior third of the body, a simple slitlike opening which is very difficult to find, there being no protruding lips. The fact that in

C. americanum the mouth capsule is a little wider than long, in *C. brantae* considerably longer than wide, and that the bursa of the new species (fig. 8) is larger than that of *C. americanum*, although the worm itself is smaller, are distinctive characters which catch one's attention when specimens of the two species are compared. The position of the vulva, the length of the spicules, and the host in which the nematode is found differentiate *C. brantae* from the seven previously described species as they are given by Chapin (2) and by the writer (5).

CONCLUSION

The eight parasitic nematodes mentioned above as having been discovered recently in North America include such diverse groups as strongyles, spirurids, and capillarids, while the hosts, including the chicken, turkey, domestic and wild geese, wild ducks, carrier and domestic pigeons, ruffed grouse, and quail, are all economically important birds. The finding within less than a year and a half that parasitic nematodes are responsible for such a variety of previously unrecognized pathological conditions in birds suggests that the rôle played by these parasites has been considerably underestimated and that other significant forms will doubtless be found in this country if sufficient search is made for them.

LITERATURE CITED

- (1) BUNYEA, H., and CREECH, G. T.
1926. THE PATHOLOGICAL SIGNIFICANCE OF GIZZARD-WORM DISEASE OF GEESSE. North Amer. Vet. 7 (6): 47-48, illus.
- (2) CHAPIN, E. A.
1925. REVIEW OF THE NEMATODE GENERA SYNGAMUS SIEB. AND CYATHOSTOMA E. BLANCH. Jour. Agr. Research 30: 557-570, illus.
- (3) CRAM, E. B.
1926. A PARASITIC NEMATODE AS THE CAUSE OF LOSSES AMONG DOMESTIC GEESSE. North Amer. Vet. 7 (1): 27-29, illus.
- (4) ———
1926. A PARASITIC DISEASE OF THE ESOPHAGUS OF TURKEYS. North Amer. Vet. 7 (10): 46-48, illus.
- (5) ———
1927. BIRD PARASITES OF THE NEMATODE SUBORDERS STRONGYLATA, ASCARIDATA, AND SPIRURATA. U. S. Natl. Mus. Bul. 140, 465 p., illus.
- (6) HUNG, S. L.
1926. PATHOLOGICAL LESIONS CAUSED BY CAPILLARIA ANNULATA. North Amer. Vet. 7 (10): 49-50, illus.
- (7) JOEST, E.
1915. MITTEILUNGEN ÜBER EINIGE BESONDERS BEMERKENSWERTE FÄLLE ZUR HISTOLOGIE DER DURCH DEN STRONGYLUS NODULARIS RUD. BEDINGTEN "MAGENWURMSKUCHEN" JUNGER GÄNSE. Ber. K. Tierärztl. Hochsch. Dresden (n. F., 1914) 9: 94-96.
- (8) STEVENSON, E. C.
1904. A NEW PARASITE (STRONGYLUS QUADRIRADIATUS N. SP.) FOUND IN THE PIGEON. (PRELIMINARY REPORT.) U. S. Dept. Agr., Bur. Anim. Indus. Circ. 47, 6 p., illus.

ORGANIZATION OF THE UNITED STATES DEPARTMENT OF AGRICULTURE

January 7, 1923

<i>Secretary of Agriculture</i>	W. M. JARDINE.
<i>Assistant Secretary</i>	R. W. DUNLAP.
<i>Director of Scientific Work</i>	A. F. WOODS.
<i>Director of Regulatory Work</i>	WALTER G. CAMPBELL.
<i>Director of Extension</i>	C. W. WARBURTON.
<i>Director of Personnel and Business Administration</i>	W. W. STOCKBERGER.
<i>Director of Information</i>	NELSON ANTRIM CRAWFORD.
<i>Solicitor</i>	R. W. WILLIAMS.
<i>Weather Bureau</i>	CHARLES F. MARVIN, <i>Chief</i> .
<i>Bureau of Animal Industry</i>	JOHN R. MOHLER, <i>Chief</i> .
<i>Bureau of Dairy Industry</i>	L. A. ROGERS, <i>Acting Chief</i> .
<i>Bureau of Plant Industry</i>	WILLIAM A. TAYLOR, <i>Chief</i> .
<i>Forest Service</i>	W. B. GREELEY, <i>Chief</i> .
<i>Bureau of Chemistry and Soils</i>	H. G. KNIGHT, <i>Chief</i> .
<i>Bureau of Entomology</i>	C. L. MARLATT, <i>Chief</i> .
<i>Bureau of Biological Survey</i>	PAUL G. REDINGTON, <i>Chief</i> .
<i>Bureau of Public Roads</i>	THOMAS H. MACDONALD, <i>Chief</i> .
<i>Bureau of Agricultural Economics</i>	LLOYD S. TENNY, <i>Chief</i> .
<i>Bureau of Home Economics</i>	LOUISE STANLEY, <i>Chief</i> .
<i>Federal Horticultural Board</i>	C. L. MARLATT, <i>Chairman</i> .
<i>Grain Futures Administration</i>	J. W. T. DUVEL, <i>Chief</i> .
<i>Food, Drug, and Insecticide Administration</i>	WALTER G. CAMPBELL, <i>Director of Regulatory Work, in Charge</i> .
<i>Office of Experiment Stations</i>	E. W. ALLEN, <i>Chief</i> .
<i>Office of Cooperative Extension Work</i>	C. B. SMITH, <i>Chief</i> .
<i>Library</i>	CLARIBEL R. BARNETT, <i>Librarian</i> .

This bulletin is a contribution from

<i>Bureau of Animal Industry</i>	JOHN R. MOHLER, <i>Chief</i> .
<i>Zoological Division</i>	MAURICE C. HALL, <i>Chief</i> .

10

ADDITIONAL COPIES
OF THIS PUBLICATION MAY BE PROCURED FROM
THE SUPERINTENDENT OF DOCUMENTS
U.S. GOVERNMENT PRINTING OFFICE
WASHINGTON, D. C.
AT
5 CENTS PER COPY
▽

END