



AgEcon SEARCH
RESEARCH IN AGRICULTURAL & APPLIED ECONOMICS

The World's Largest Open Access Agricultural & Applied Economics Digital Library

This document is discoverable and free to researchers across the globe due to the work of AgEcon Search.

Help ensure our sustainability.

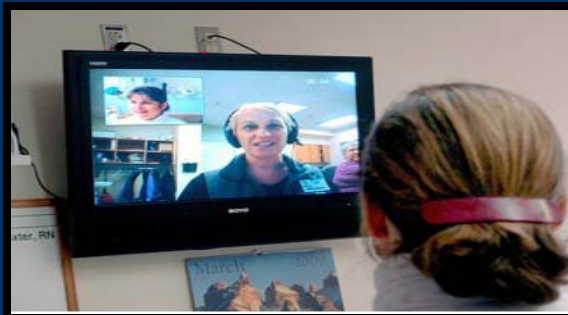Give to AgEcon Search

AgEcon Search

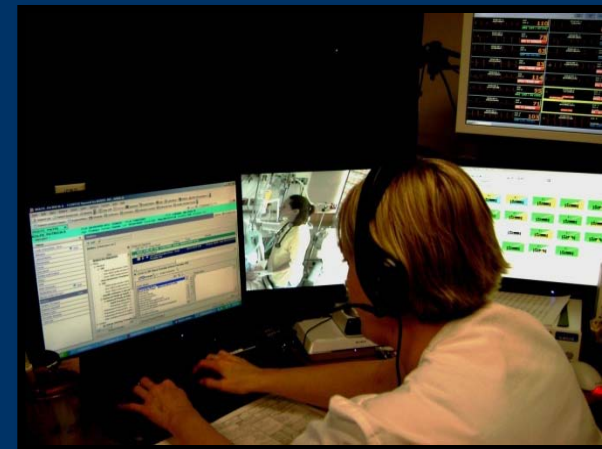
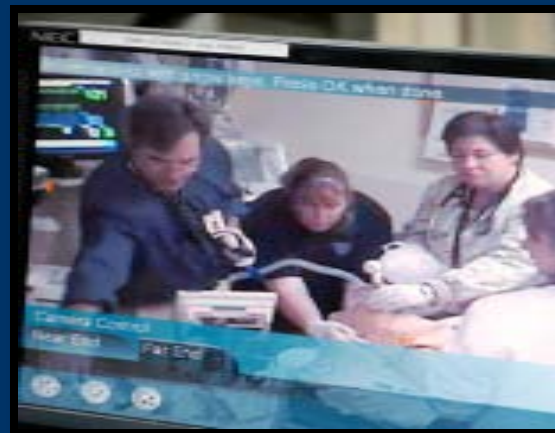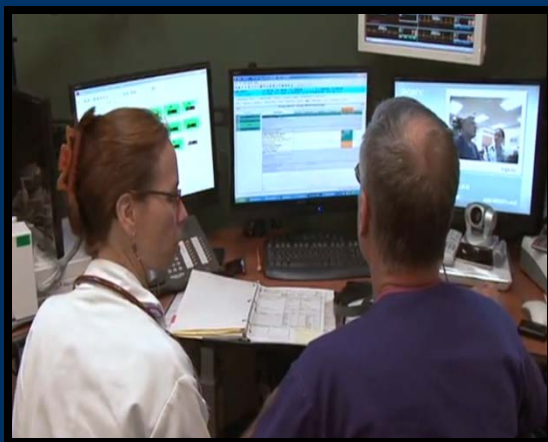<http://ageconsearch.umn.edu>

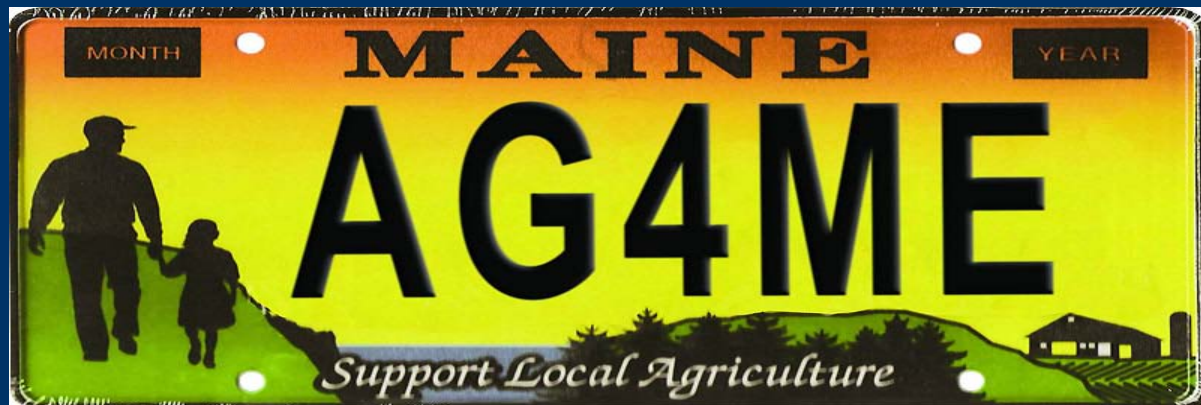
aesearch@umn.edu

*Papers downloaded from **AgEcon Search** may be used for non-commercial purposes and personal study only. No other use, including posting to another Internet site, is permitted without permission from the copyright owner (not AgEcon Search), or as allowed under the provisions of Fair Use, U.S. Copyright Act, Title 17 U.S.C.*



Telemedicine in rural Maine





Mary McCarthy

Nurse Manager

Telemedicine Center

Eastern Maine Medical Center

mmcarthy@emh.org

USDA Outlook Forum

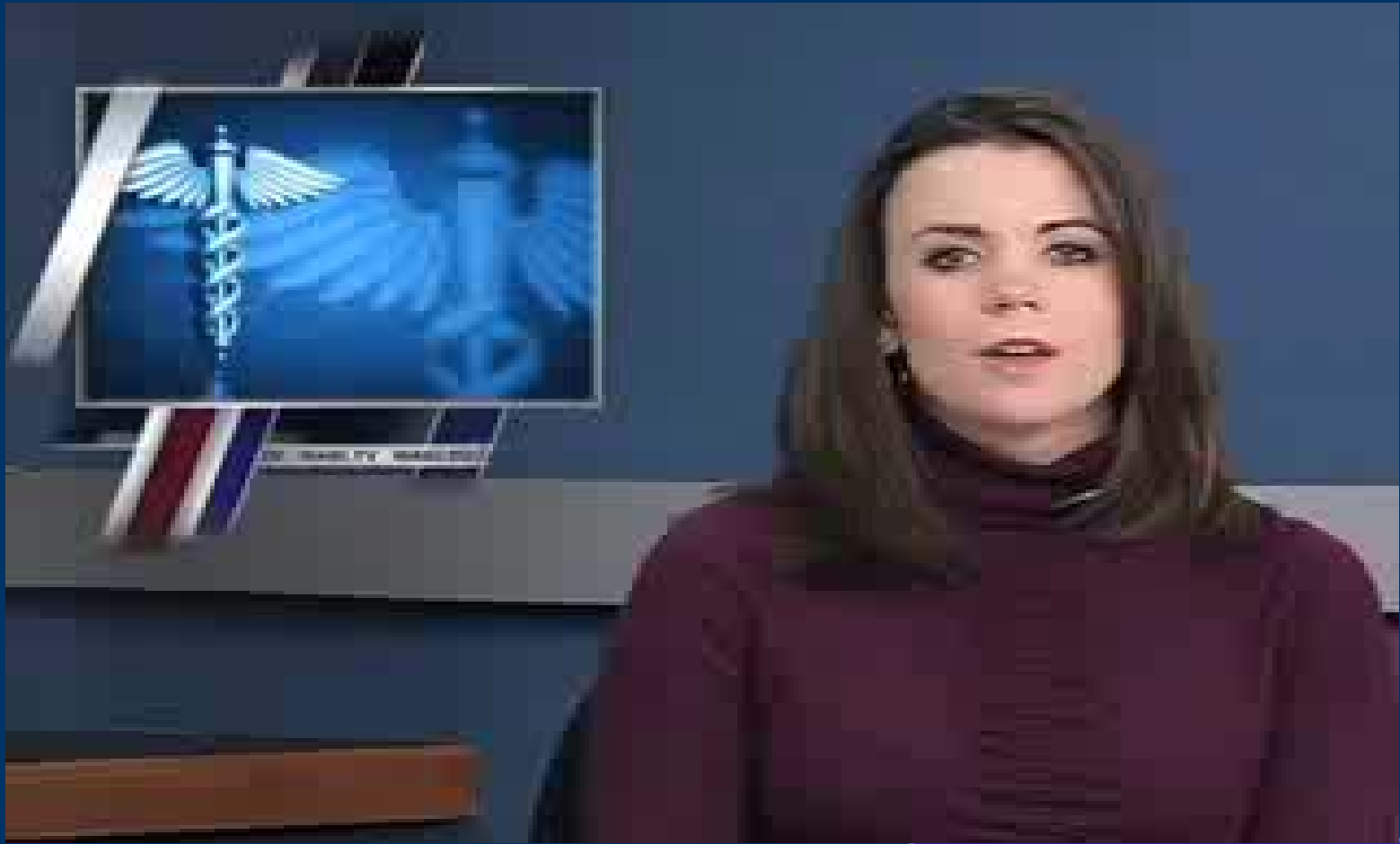February 25th, 2011

Eastern Maine Medical Center 1861



Eastern Maine Medical Center 2010





WABI TV 5
Spirit of Maine


Eastern Maine
Medical Center™
Inspiring confidence in care

TOGETHER We're Stronger

EMHS
MEMBER

Telemedicine in rural America would not be possible without grant funding

2006 to 2010

United States

Department of Agriculture

USDA

grant funding for *Eastern
Maine Medical Center's*
service area

\$1,607,000

2006 to 2010

Health Resources and
Services Administration

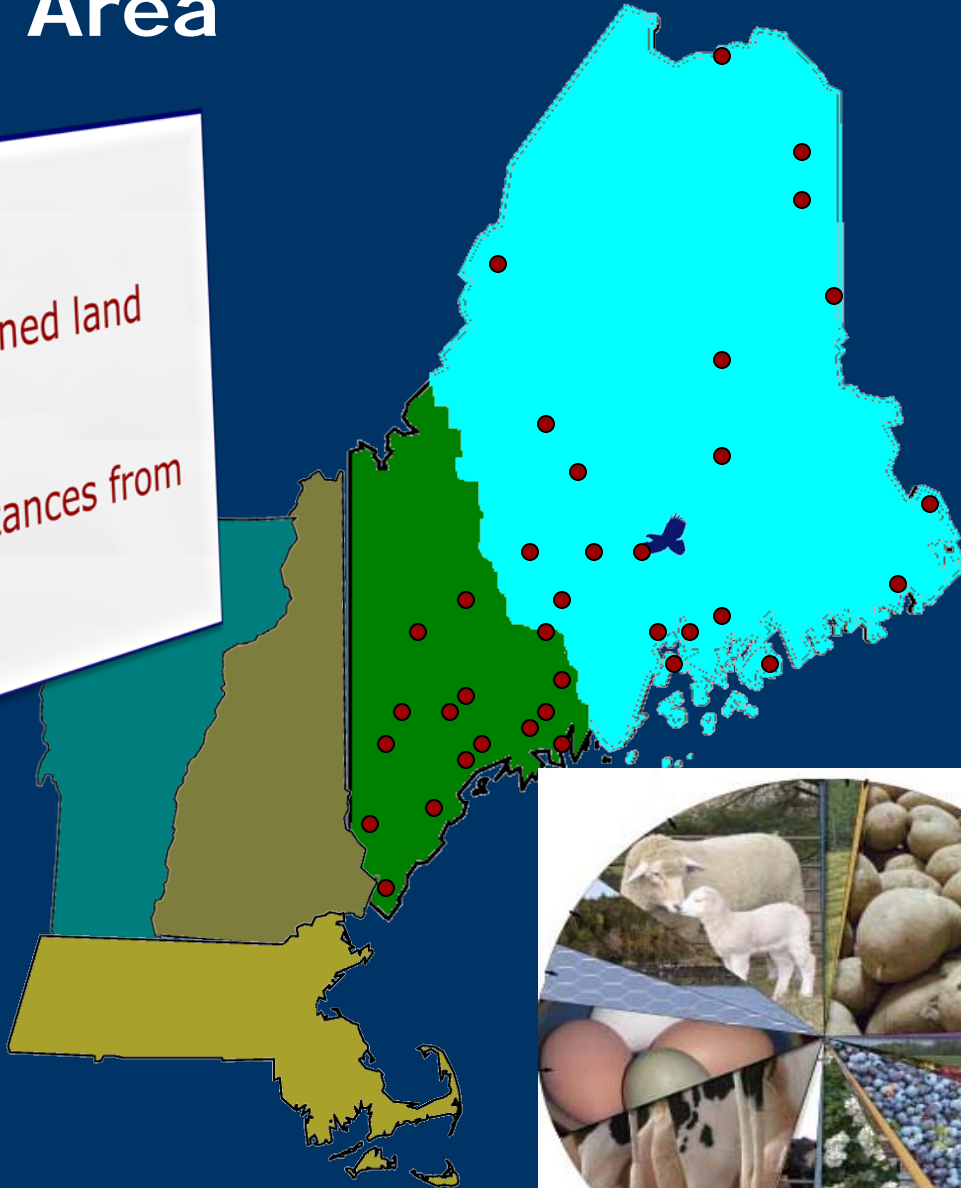HRSA

grant funding for *Eastern
Maine Medical Center's*
service area

\$1,500,000

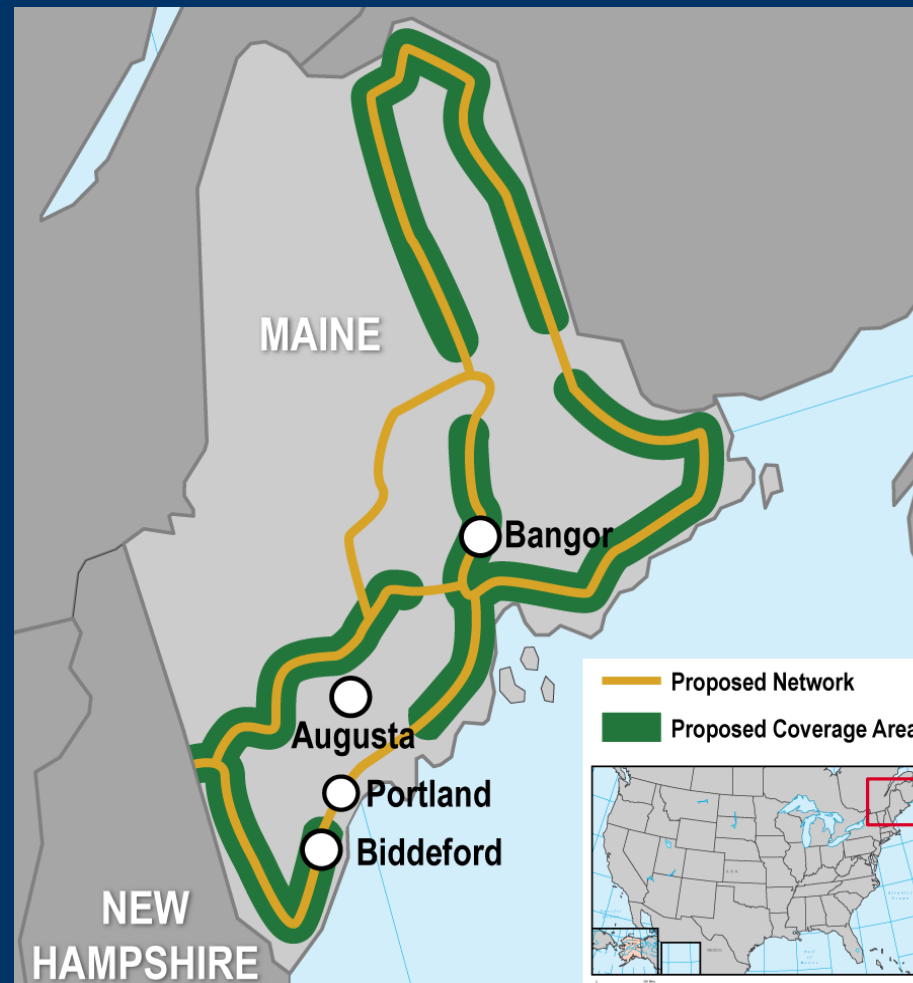
EMMC Service Area

- ✦ 26,000 square miles
- ✦ Roughly equals combined land mass of NH, VT, & MA
- ✦ Ground transport distances from 3 to 210 miles



3 Ring Binder Project

- \$25.4 Million in stimulus funding from the U.S. Department of Commerce
- Installation of 1,100 miles of fiber optic cable
- Will connect more than 100 rural Maine communities




Telemedicine Services

- ICU adult
- ICU pediatric
- Trauma
- Stroke
- Pharmacy
- Oncology
- Rehabilitation
- Behavioral Health

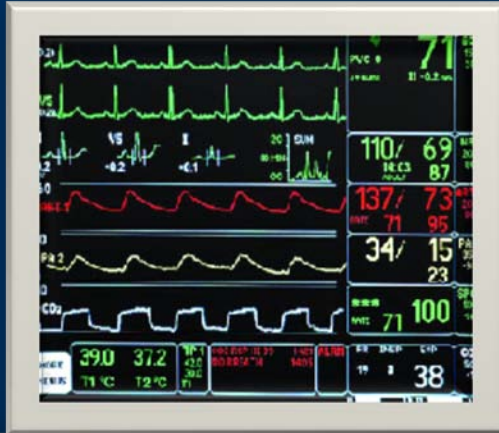Tag Krankengeschichte

4.9.18 Stenoglossifera:
 Große Anwesenheit 6 Tage mit einem Ring über die Fingerringe
 Dieser kam 2. mit Kröpfen mit dem v. kleinen Finger in den
 Fingerring der Stenoglossifera, die kl. Finger wurde verlegt, die An-
 wesenigen der Stenoglossifera wurde gegallt. Fort. wurde sofort
 zum Kröpfenverpft verhalten in dem auf dem Throna Sillbgenort
 geburft;

Befund:
 Mittelgroßer, jugendlich aussehender Mann mit kräftigen Kröpfen
 hat v. gut entwickelten Metatarsen.
 Am v. phalanx Finger befindet sich eine klaffende, stetig blutende
 Wunde, die von der Fingerringe bis zur Mitte der Mittelphalanx
 sich erstreckt und in ihrer Länge von der
 funktionierten Kröpfen nach, der Gelenk
 zwischen der 2ten Mittelphalanx ist verengt.
 Auf der Innenseite der Kröpfen blüht die Wunde
 sehr v. frisch mit abgegriffene kleinen Teil
 der Kröpfenrinne nach.
 Befundlos.

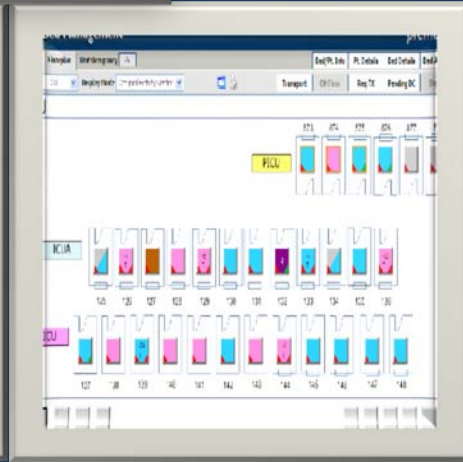

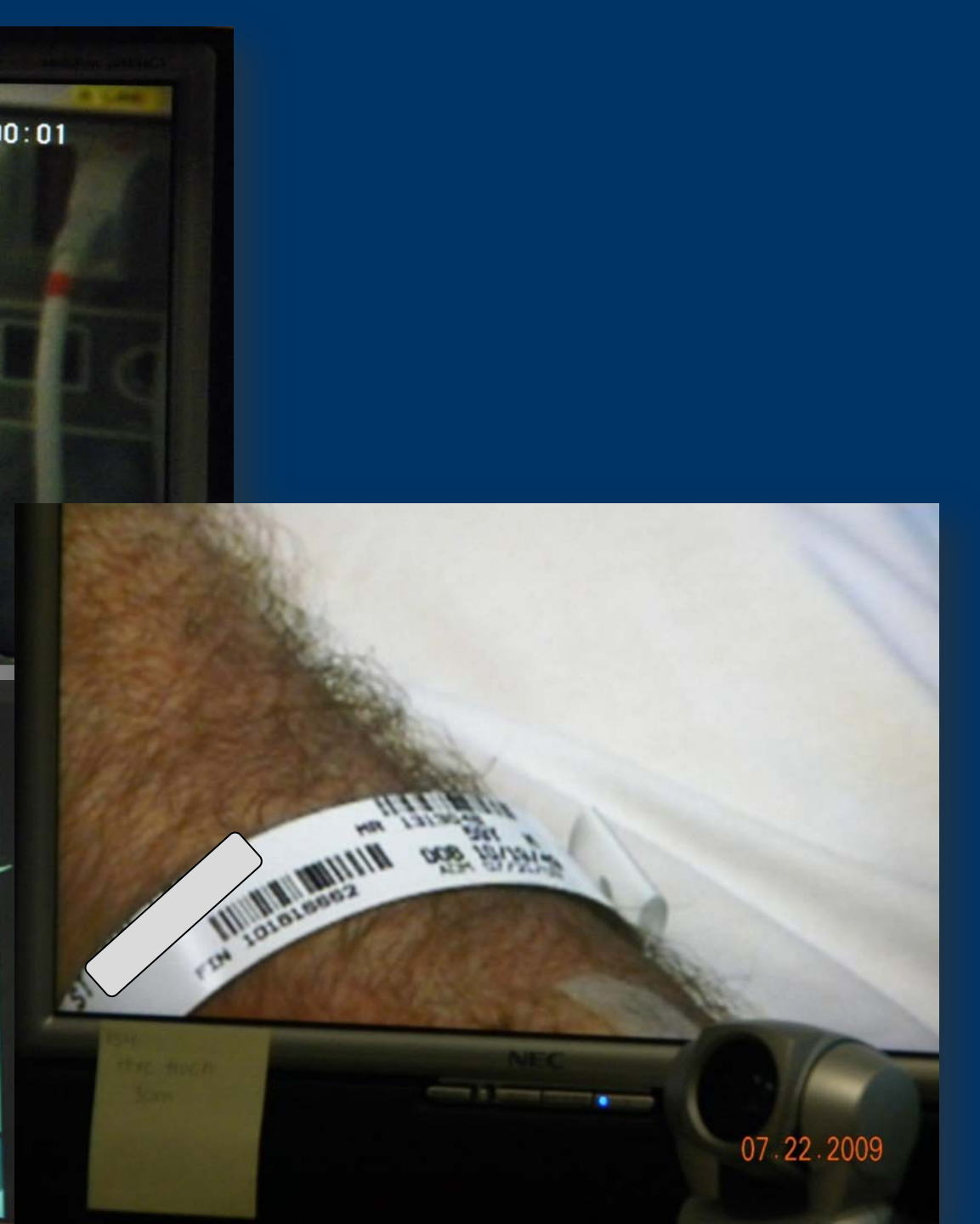
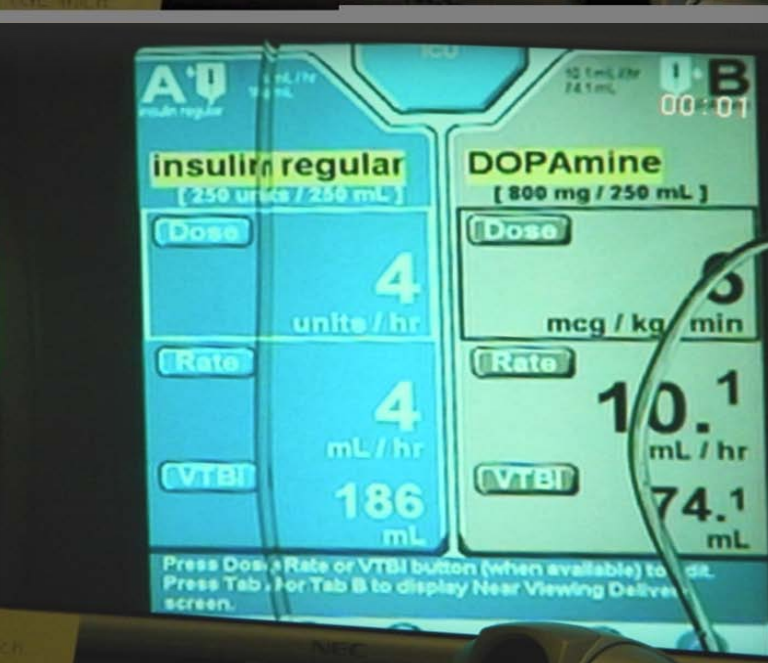
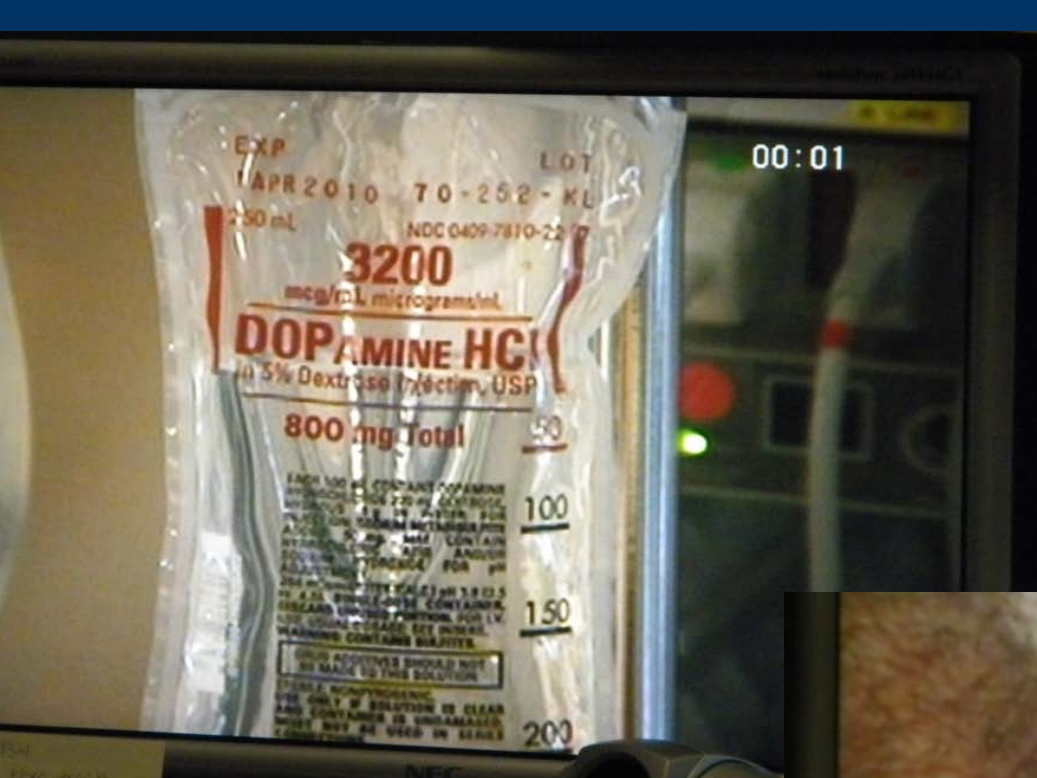
The Medical Record



Medical software interface showing patient history and vital signs over time.

Parameter	Value	Unit
Temp	37.2	°C
HR	71	bpm
BP	110/69	mmHg
SpO2	95	%
Respiration	15	breaths/min
CO2	23	mmHg





Planning and Implementation

- **Grant funding**
- **Broadband capacity**
- **Team**
 - Administration
 - Planning
 - Research
 - Information Systems
 - Information Technology
 - Accounting
 - Champions from specialty areas





TOGETHER We're Stronger

Thank You!